

Polymeric Membrane Dressings* in the Management of Infants with Epidermolysis Bullosa (EB)



Jacqueline Denyer, EB Nurse Consultant (paediatric)
Great Ormond Street Hospital and DeBRA UK
Jackie.denyer@debra.org.uk

INTRODUCTION

Epidermolysis bullosa (EB) comprises a group of genetically determined skin disorders. The common factor is the tendency for the skin and mucous membranes to break down in response to minimal everyday trauma and friction. Depending on the type of EB, prognosis varies from minor blistering on the hands and feet to progressive disability and in its most severe form death occurs in early infancy from a combination of failure to thrive and laryngeal disease.

Neonates with severe forms of EB pose a particular problem as they often have extensive wounds present pre-natally and compounded by birth trauma. Effective and sustained analgesia for procedural pain can be difficult to prescribe in this age group due to risk factors and therefore speed is of the essence in dressing changes. This must be balanced with the need for careful positioning of dressings in order to minimise contractures and deformity in those with dystrophic EB. Care must be taken to ensure no damage results from friction from the edges of dressing materials or skin stripping from inappropriate use of adhesives or unsuitable dressings.

A common problem with such wounds is an offensive odour and this is of particular concern in neonates as it has the potential to interrupt the important bonding process with parents who may already be struggling to bond with an infant who has such visible disabilities and in whom normal handling is compromised.

Before polymeric membrane dressings* was used in affected neonates and infants a combination of other dressing materials was selected in order to ensure non adherence, control exudate and offer protection from added trauma caused by handling and normal baby movements. The wounds were slow to heal and dressing changes were prolonged due to the layering of dressing materials.

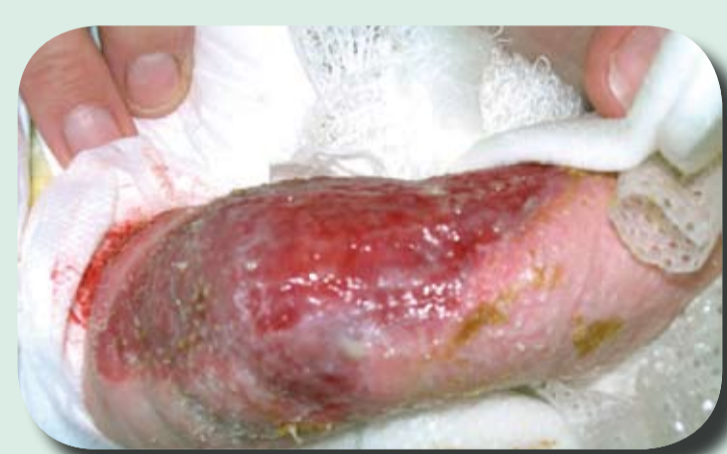AIM

To evaluate the use of polymeric membrane dressings with a built in wound cleanser/surfactant and superabsorbent on neonates and infants.

CASE STUDY

Matthew is the second child of unrelated parents. Following an uneventful pregnancy and normal delivery he was noted to have a large deep wound extending over his right foot and leg. He had a smaller wound on his left foot and ankle. Blistering developed around the edges of his nappy and on his tongue and gums. A skin biopsy taken on day 2 showed Matthew has Severe Generalised Dystrophic Epidermolysis Bullosa.

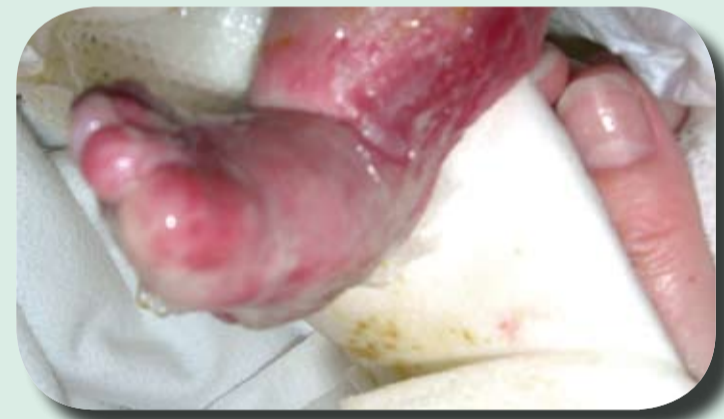9 October 2008



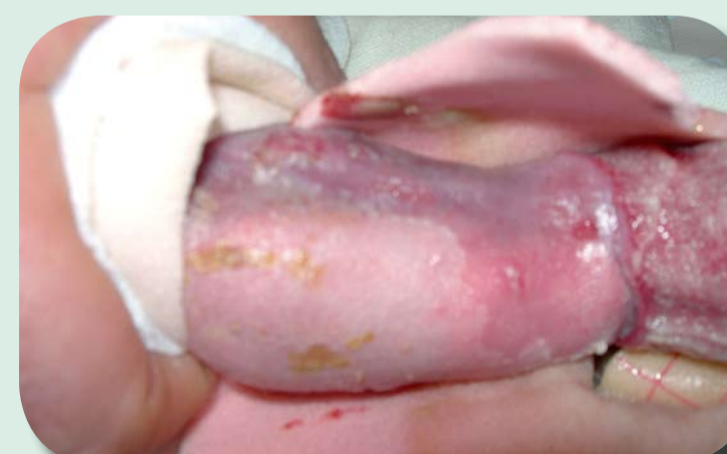His wounds were dressed immediately after birth with paraffin tulle and dry gauze which resulted in further skin loss to the wounds following traumatic removal of the inappropriate dressing materials.

The lesions were then dressed with dressings proven to be autramatic on those with severe EB. In addition to this strips of hydrofibre dressings were placed between his toes in an attempt to avoid digital fusion which is a feature of dystrophic EB. Over the next few days it was noted that the wounds became very moist with an offensive smelling exudate. Matthew remained well and showed no symptoms of a systemic infection.

9 October 2008



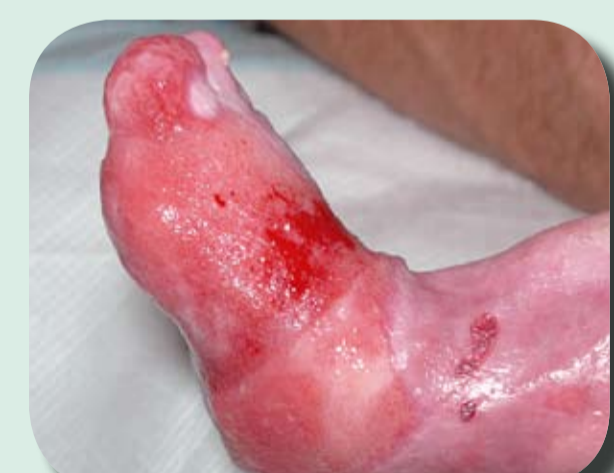20 November 2008



Polymeric membrane dressings were then applied and changed on alternate days because of the copious amounts of exudate. Initially the quantity of exudate saturated the dressings within 24 hours and in order to avoid subjecting the baby to daily dressings the film backing was scored and a thicker version of the polymeric membrane dressing was placed over it to absorb the excess.

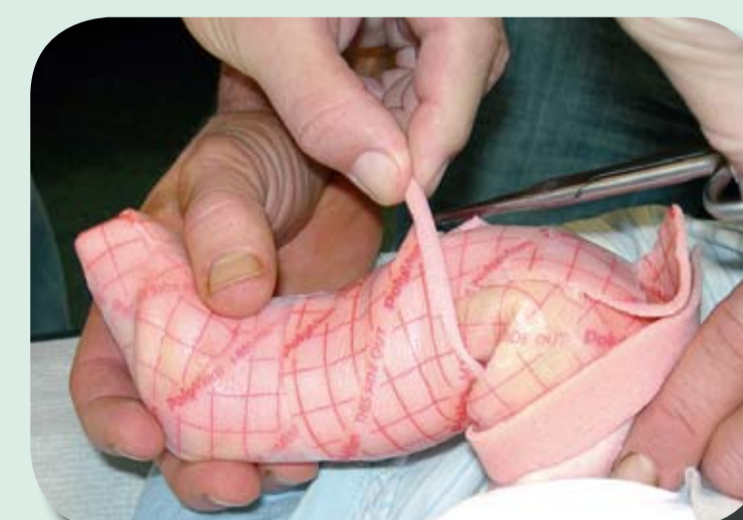Rapid healing was observed and the thicker version was discontinued. We were able to reduce dressing changes to every 3-4 days in response to the reduction in exudate. Dressing change time decreased greatly due to the ease of application and removal of

polymeric membrane dressings and the use of a single sheet dressing rather than a wound contact layer plus a secondary dressing. As these dressings contains a cleanser it was not necessary to add antimicrobial agents.

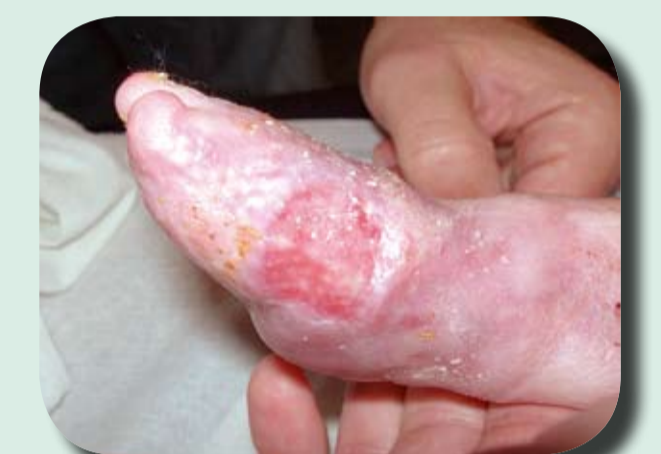

27 November 2008. Right foot after one week's treatment with polymeric membrane dressings

2 December 2008

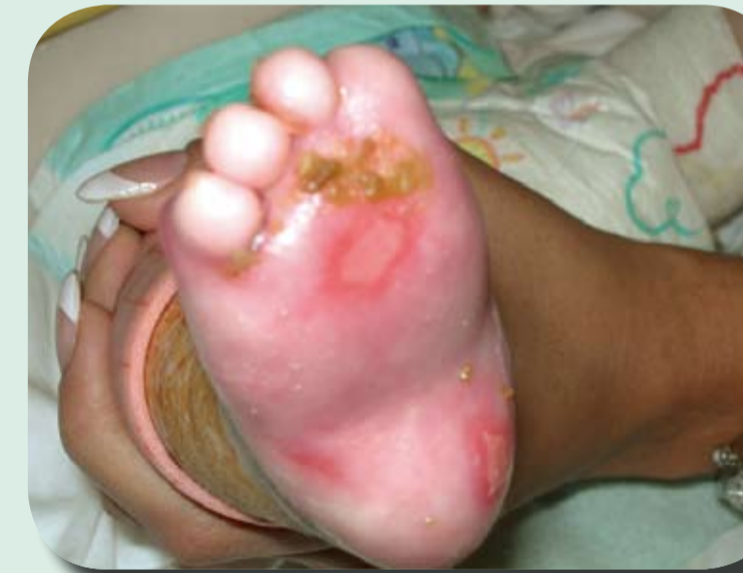

Breakdown of these and other new areas continue to occur regularly following trauma. Due to the fragility of his skin and difficulties in prevention of damage when all dressings are removed at anyone time we are unable to bathe Matthew. Polymeric membrane dressings continues to be the dressing of choice and it has been noted that wound infection and critical colonisation have been less frequent than previously experienced in other similarly afflicted infants using traditional dressings.



2 December 2008. Right foot after one month's treatment with polymeric membrane dressings

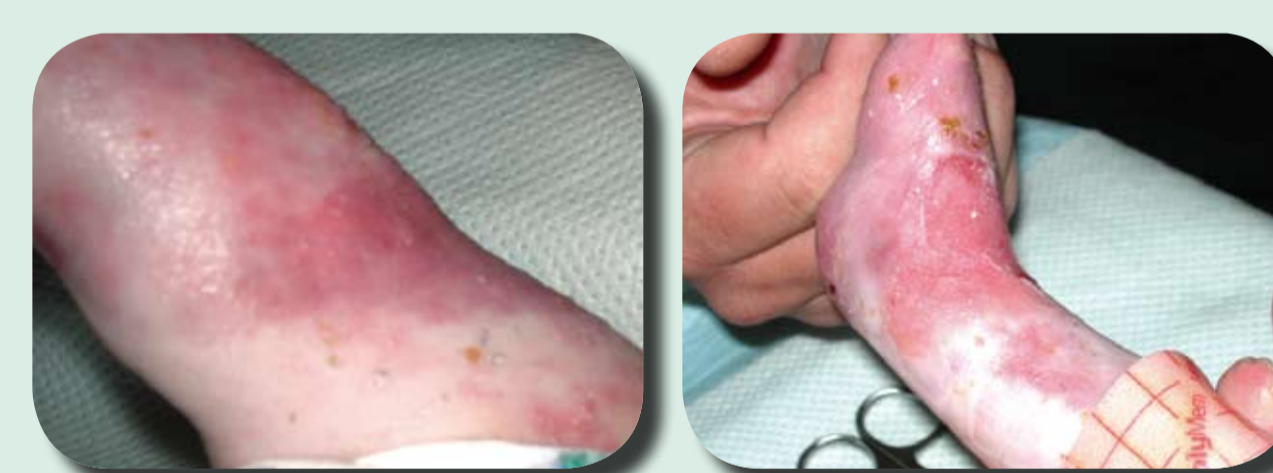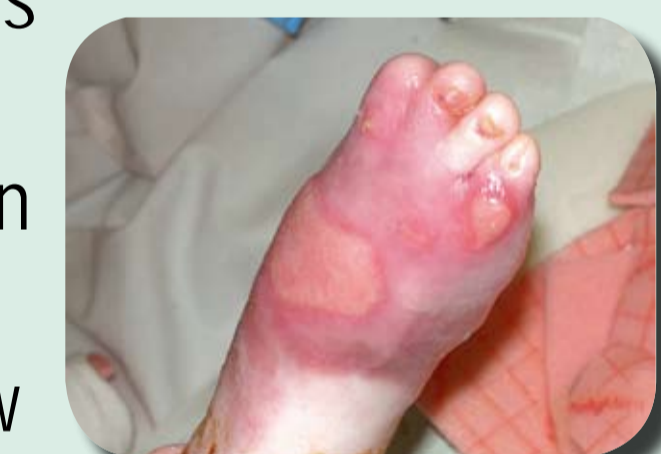31 March 2009



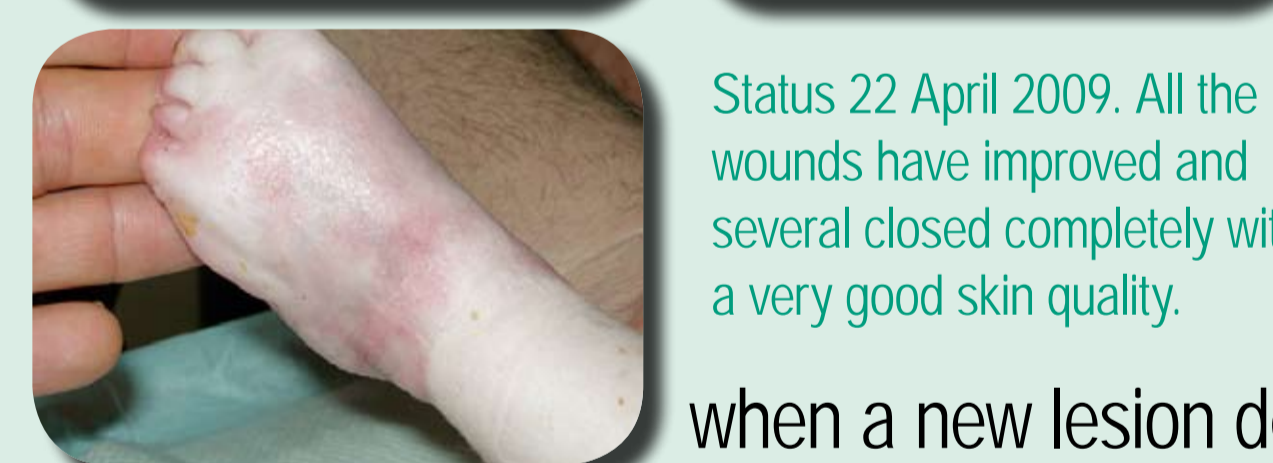Despite rigorous measures to prevent digital fusion, Matthew, now aged 7 months, has pseudo syndactyly of several toes which is an indication of the severity of his EB.

He has also demonstrated early complications including sloughing of the entire lining of his oesophagus which necessitated an admission to PICU. Subsequent scarring of the mucosa has left him at risk of aspiration and he is now allowed nothing by mouth and is fed via a gastrostomy.

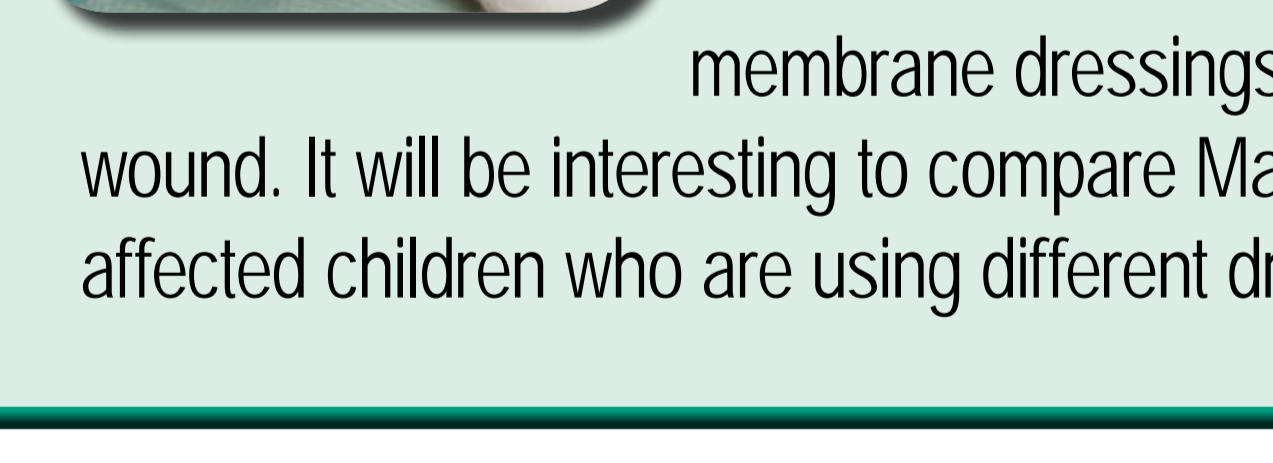
31 March 2009



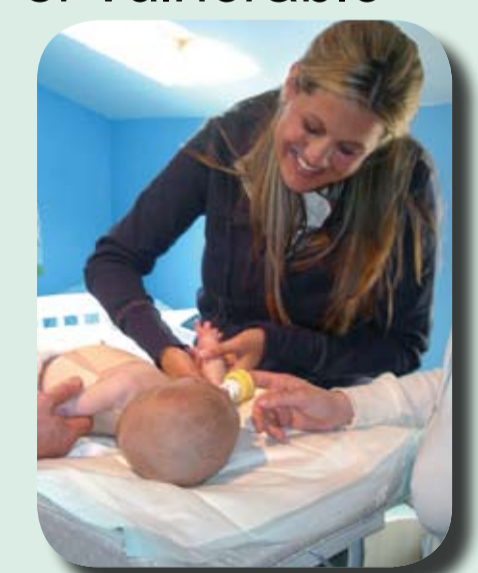Infants with this level of severity of dystrophic EB generally demonstrate a higher incidence of chronic wounds by this age. The quality of skin over healed areas is better than generally predicted in infants with this form of EB who have suffered such extensive prenatal damage. By continuing to use polymeric membrane dressings for protection of vulnerable healed areas we have noted that



Status 22 April 2009. All the wounds have improved and several closed completely with a very good skin quality.



when a new lesion develops the action of the polymeric membrane dressings appears to inhibit progression of the wound. It will be interesting to compare Matthew's progress with similarly affected children who are using different dressing regimens.



METHOD

Severely affected neonates who presented with wounds at birth were selected for the study. Factors considered were:

- Ease of application and removal.
- Control of odour and exudate.
- Healing
- Quality of healed skin
- Duration of dressing changes
- Reduction in pain. (FLACC)

RESULTS

The time taken in dressing changes was greatly reduced compared to the previous method. In the case study the dressing change was completed in 25 minutes, a reduction of 30 minutes compared with the previous dressing regimen. The dressing was easy to apply and to remove. Initially the wound exudate seemed to increase but the thick version of polymeric membrane dressings handled the exudate quite well. Odour decreased when using these dressings. More rapid healing was noted than with the previously recommended dressing regimen. We

have noted a better skin quality following healing and the slower tendency for it to break down again. By using polymeric membrane dressings on healed areas for protection we have also noted where there is a new lesion following trauma or a blister the action of the polymeric membrane dressings seems to prevent the wound from developing.

Pain scoring using the FLACC scoring system reduced from 8 to 4. (A validated behavioral scale for scoring pain in young children with a scale from 0 to 10)

DISCUSSION

Before polymeric membrane dressings were used in affected neonates and infants a combination of other dressing materials were selected in order to ensure non adherence, control exudate and offer protection from added trauma from both handling and normal baby movements. The wounds took several weeks to heal and dressing changes were prolonged due to the layering of dressing materials.

The study demonstrated a rapid improvement in wound size in all cases. Of particular importance is the reduction of time during dressing changes in this vulnerable age group. It will be interesting to compare skin quality and number of chronic wounds with children with similar severity of EB as this cohort grow older.

*PolyMem® and PolyMem® MAX Wound dressings
Manufactured by Ferris Mfg Corp, Burr Ridge, IL 60527 USA. This case study was unsponsored. Ferris Mfg. Corp. contributed to this poster design and presentation.