

REGAINING THE TRUST OF A PATIENT AND HER FAMILY IN A PAINFUL WOUND CARE SITUATION

Erna Bachmann, Brigitte Santo
Spitex Uznach-Gommiswald-Ernetschwil-Rieden, SWITZERLAND



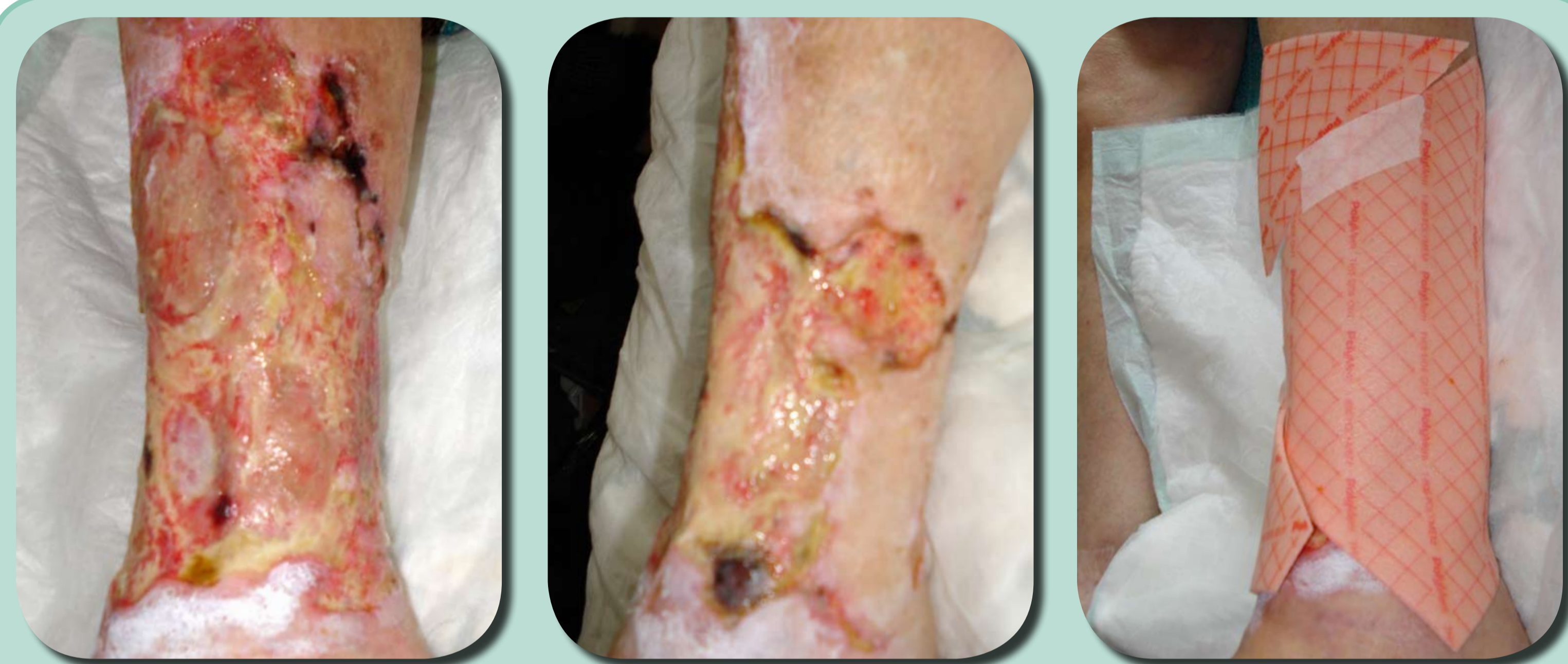
INTRODUCTION

An 88 year-old woman with diabetes, hypertension and arterial insufficiency developed 11 necrotic lesions on her left lower leg in January 2009. During her daily hospital visits debridement was performed on numerous occasions. Not only was this excruciatingly painful for the patient but they also resulted in the enlargement of the smaller lesions into one large, almost circumferential ulcer. In March the situation became so painful that the patient needed to be hospitalised at her Regional Hospital.

Vascular dilatation was performed in April followed by daily, excruciatingly painful debridement with skin grafting as a goal. A few weeks later, after an incident during debridement which caused a major bleeding, the patient could not tolerate the pain any longer and insisted on going home. Her situation did not allow her to live alone so she was discharged on the condition that she stay with her daughter. At this point her pain scores had been a constant 10 out of 10 for several months.

Due to her previous major bleeding she was instructed to visit Uznach Hospital (close to her daughters home) for dressing changes. The following dressing changes were performed alternatively at the Regional Hospital (1 hour away) and by the Home Care nurses from Uznach.

Since the patient no longer accepted that her wounds be debrided, and was terrified during dressing changes, we started by re-evaluating the dressings that were currently being used.



13 May. First time we saw the patient at her daughters home. All her previous dressings had stuck like glue and dressing changes could take over an hour with the patient moaning in pain the entire time. This was why we decided to only use polymeric membrane dressings as they eliminate the need of cleansing, do not stick to the wound surface and are effective in reducing inflammation and pain.

Aim

To find an acceptable treatment with emphasis on minimizing trauma and pain associated with dressing changes as well as finding a dressing that could continuously debride the wound.

To build up a trust between the patient and the home care nurses as she was in agony and petrified during dressing changes.

METHOD

Polymeric membrane dressings were chosen due to their pain relieving effect and ability to facilitate gentle autolytic debridement as the patient now did not agree to any more sharp debridement. Dressings were initially changed daily and later 3 times a week at the patient's home.

RESULTS

The wounds were visibly cleaner with a pain score of 3 after five day's treatment and continuing to decrease after that. The wounds showed signs of healing after nine days and were fully granulated by one month. Full closure was achieved in seven months.

DISCUSSION

Not only did the patient's pain diminish dramatically within the first week, we rapidly regained the trust of the patient and her family whose involvement in the treatment had implications for the patient's entire well-being and quality of life.

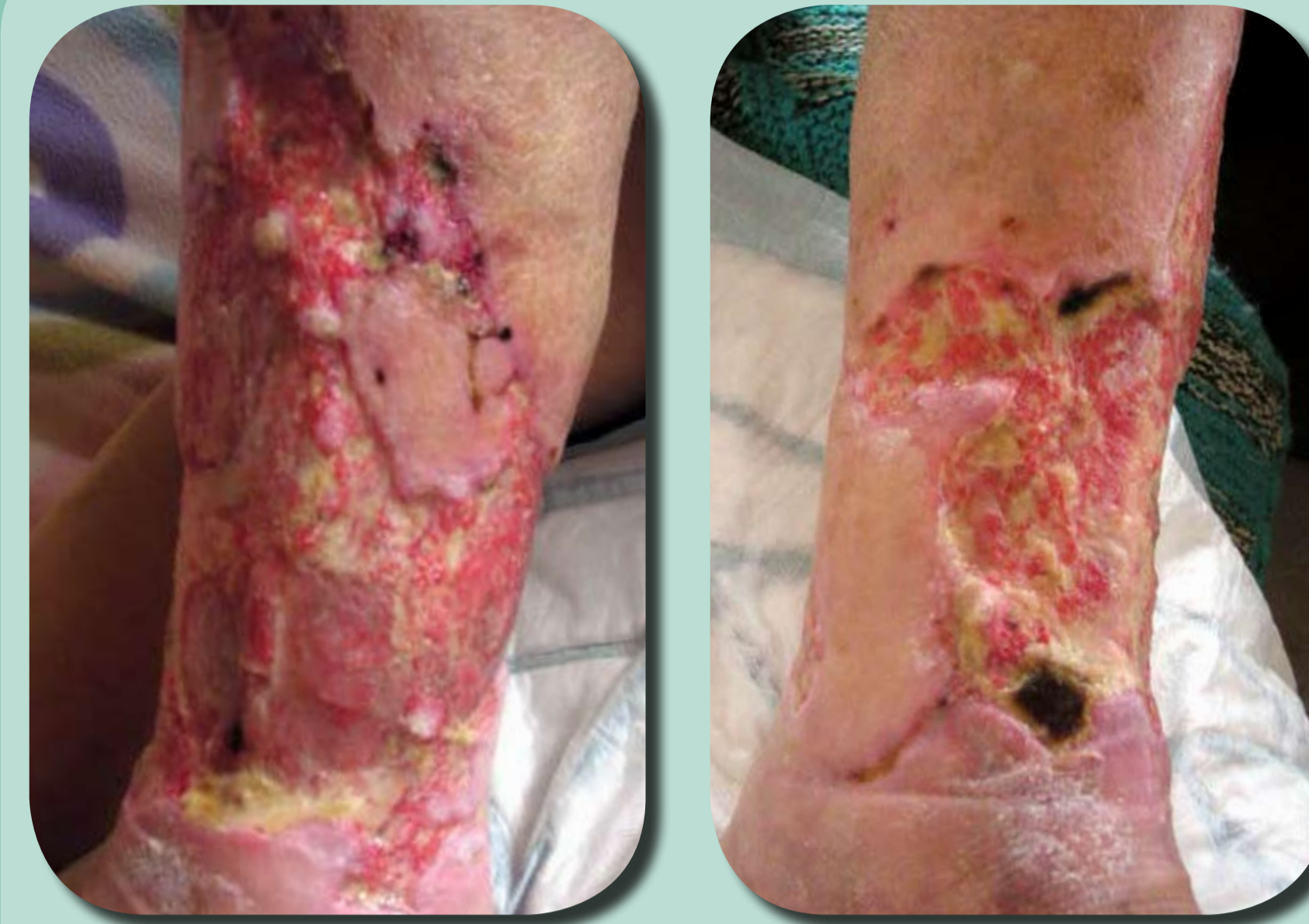After the first week with polymeric membrane dressings her daughter told us that the patient was pain free throughout the day and had started to eat again.

Initially the dressing changes had taken over 1,5 hours to perform. The dressings stuck like glue onto her wounds and were painful and time-consuming to remove. During the entire time the patient would be crying and begging us not to hurt her. Once we started to use Polymeric membrane dressings the pain diminished dramatically and it only took about 30 minutes to perform the dressing changes. Painful debridement was no longer needed.

We calculated that the cost per procedure (dressing materials and time) was reduced by at least 40 EUROS per dressing change even though we changed the polymeric membrane dressings on a daily basis the first couple of weeks.

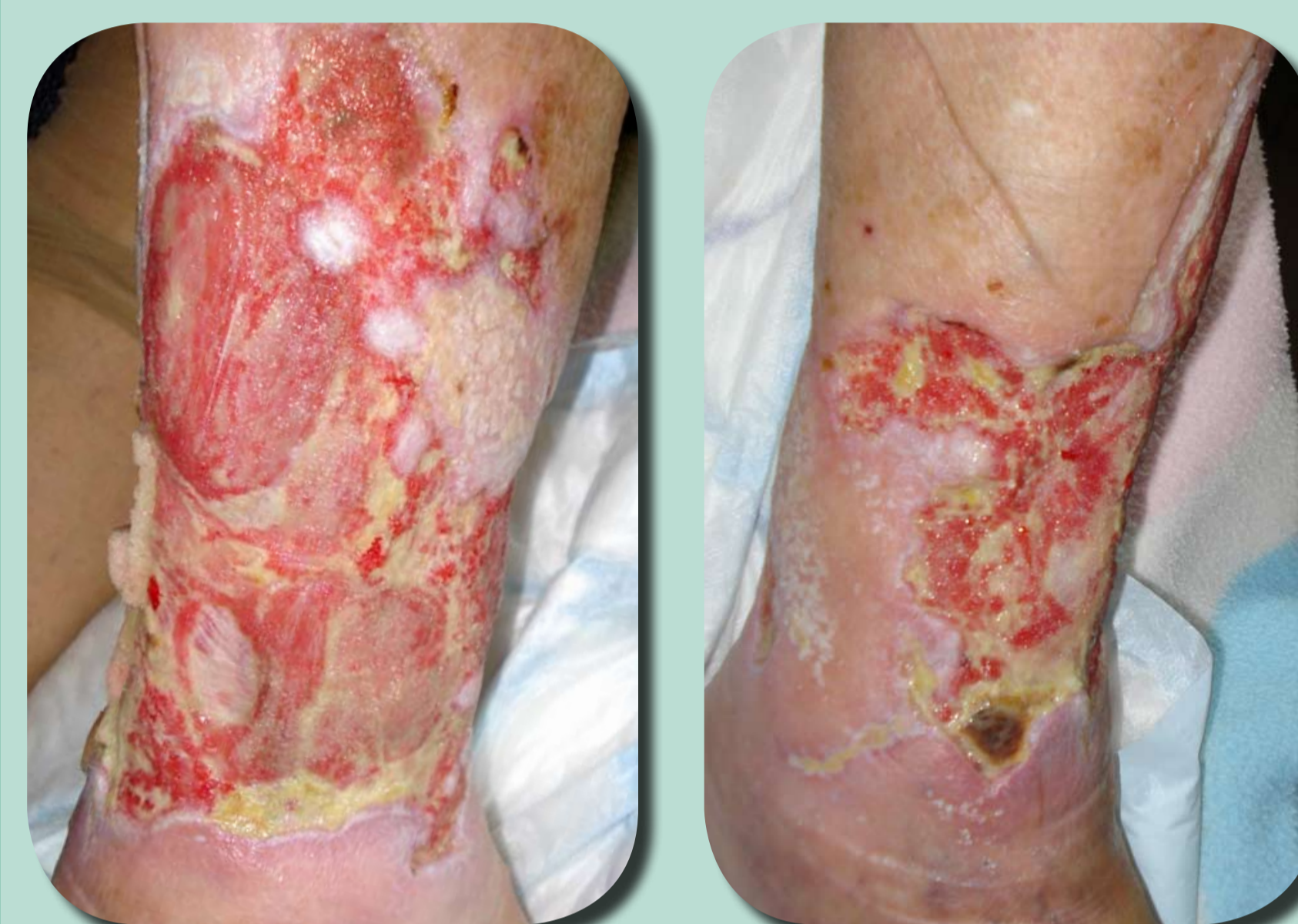Looking back we can see that we exceeded our goals, not only did we find a treatment that minimised pain, gently debrided the wound and gained the trust of the family, we also increased her quality of life and managed to close the large wound against all odds.

*PolyMem® and PolyMem® WIC Wound Dressings
Manufactured by Ferris Mfg Corp, Burr Ridge, IL 60527 USA. This case study was unsponsored.
Ferris Mfg. Corp. contributed to this poster design and presentation.



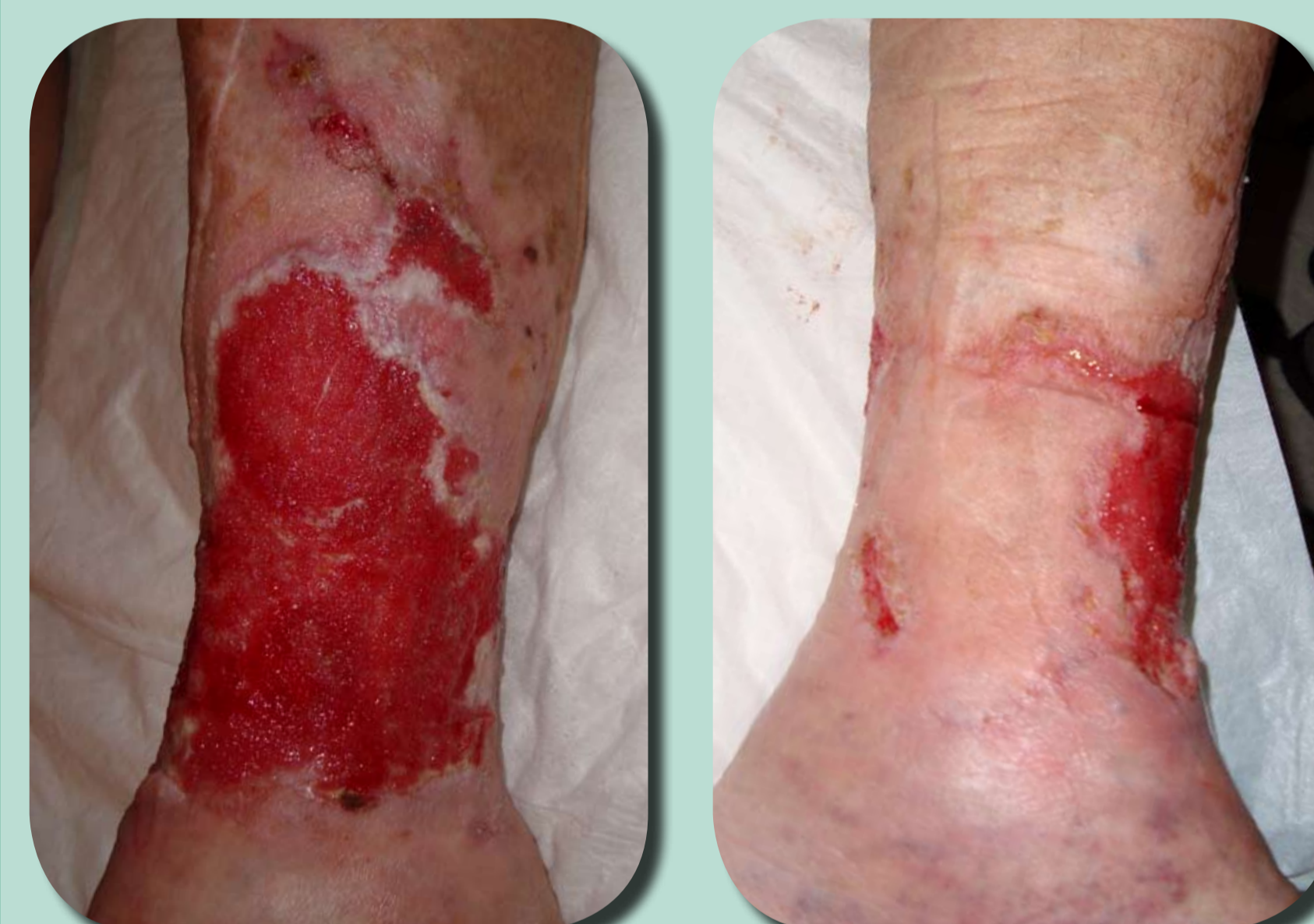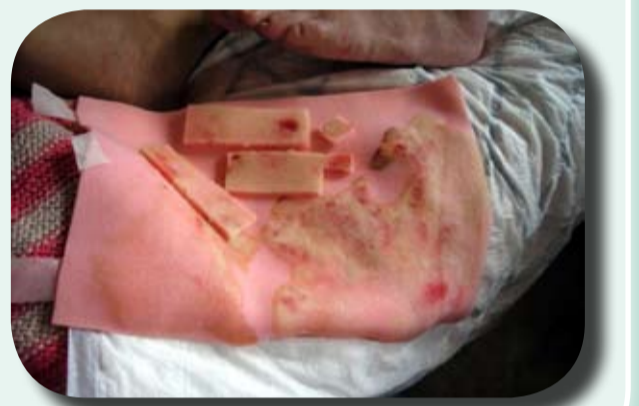18 May

The patient had only been using polymeric membrane dressings for 5 days and there was already a huge difference in the wound bed. So far there has been no cleansing during dressing changes, something the patient has been very thankful over. Due to the patients' past experience she is still quite nervous during dressing changes but admits that it doesn't hurt quite as much any more.



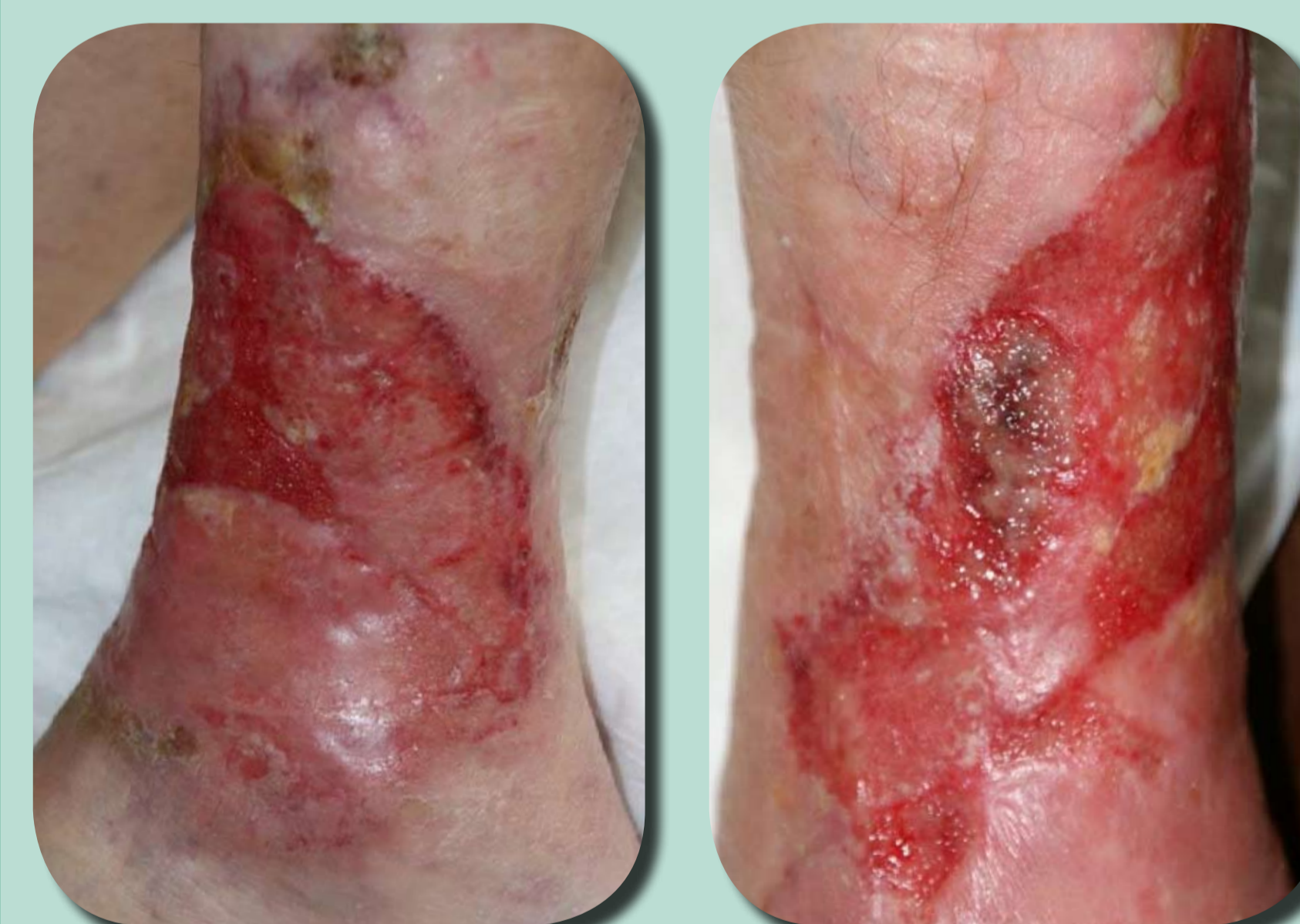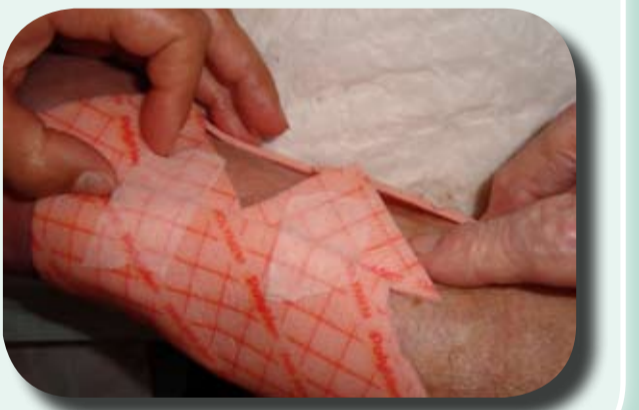22 May

It has now been one and a half weeks with polymeric membrane dressings and we notice a change not only in the improved wound bed but also the patients attitude towards us. She no longer looks terrified when we do our daily visits to change the dressings and she seems much more hopeful now that most of the wound related pain has disappeared.



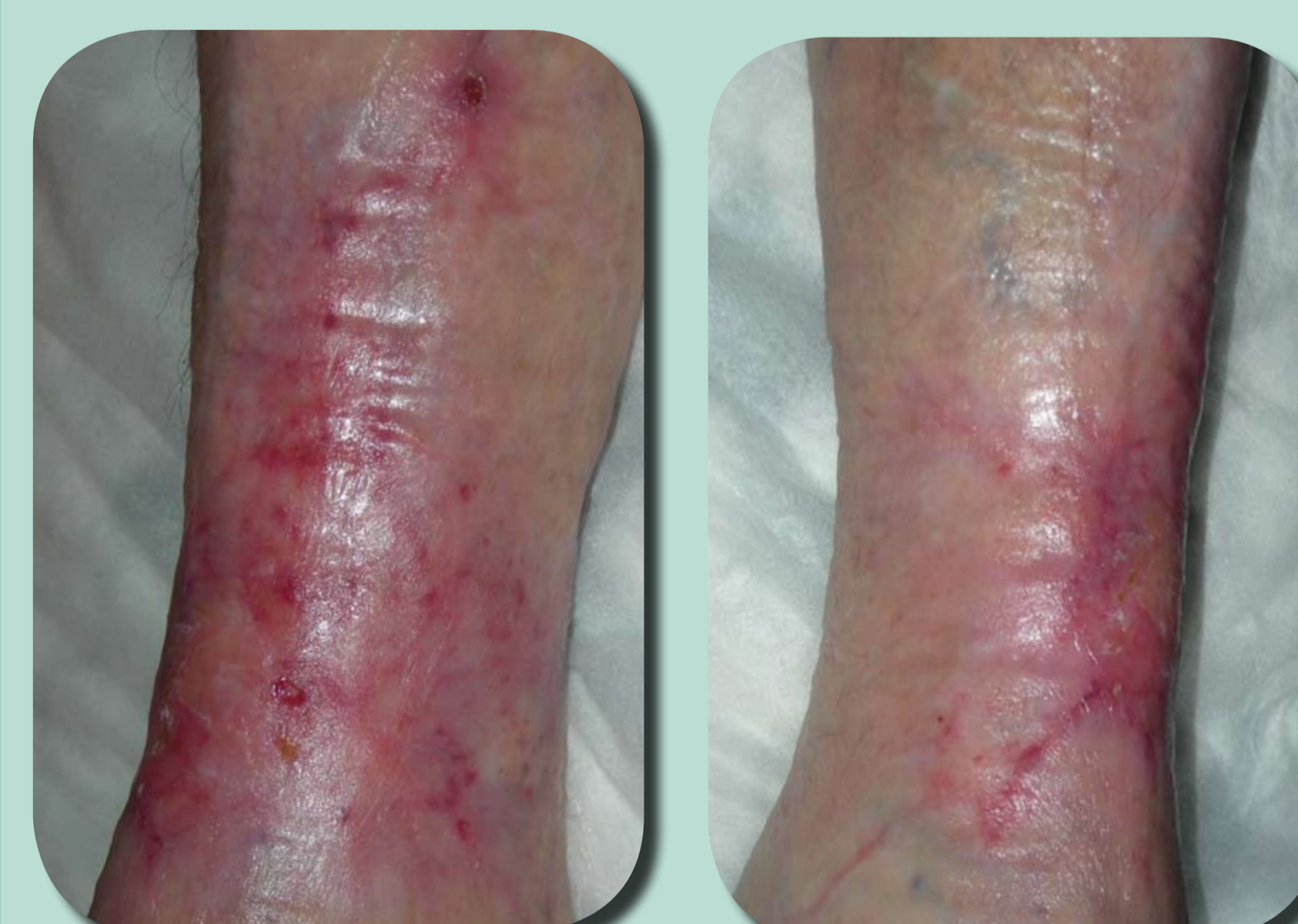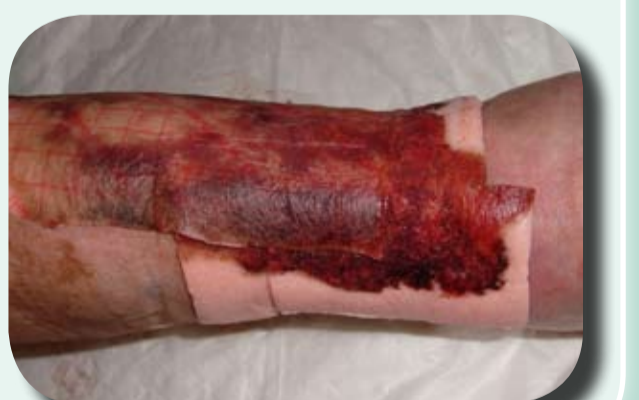June

No leg oedema for some time now. She has been to the hospital for a follow up visit where they decided that she was stable enough to move back home. Her daughter insisted that polymeric membrane dressings also be used by the new home care nurses. The wound is now fully covered with granulation tissue and large areas have already closed.



September

During the months the patient was treated at home the wound unfortunately deteriorated. The new nurses had no experience of how polymeric membrane dressings work so they made some of the classical mistakes, not changing often enough, using dressings that were too small and not making sure to overlap the sensitive surrounding skin. They also, on a couple of occasions, applied the dressing the wrong way.



December

After educating the home care nurses at the end of September, and correct application of the dressing was introduced again, the wound started to improve very quickly. In November the patient returned to the nurses in Uznach. They started to apply larger pieces of polymeric membrane dressings on the leg in order to also cover not only the wound, but also the newly healed, dry crusted areas. This speeded up the healing and seemed to reduce the scarring. Initially, what seemed like a hopeless situation turned out to have a happy ending for everyone involved.

Example of the dry crusted areas.

