

CASE STUDY

Complete Pain Relief Using Polymeric Membrane Dressings* to Treat a Category III Skin Tear to Complete Closure

Lisa Ricciardo, BSN, RN, CWS, Avalon Gardens Rehab & Health Center, 7 Route 25 A, Smithtown, NY 11787

PROBLEM

A 51-year-old female long-term-care resident suffered a fall, resulting in a large hematoma to her R lateral shin. Co-morbidities included currently well-controlled diabetes with a BMI of 31.6 and HbA1c of 5.7, chronic anemia, psoriasis with long-term topical steroid use, hypothyroidism, and recent pin placement in the L leg with a secondary infection. The patient fell a second time, breaking open the area of the hematoma into a 13.0 cm x 5 cm x 0.1 cm full-thickness skin tear. Steri-strips were applied, but the ER personnel found no salvageable flap and were unable to suture the wound. The patient was sent back to her room with antibiotic ointment and a non-adherent dressing to be changed twice a day. She was seen by the wound team the day following the second fall.

This case study was unsponsored. Ferris Mfg. Corp. contributed to the presentation of this poster.

*PolyMem® Dressings, PolyMem Silver™ Dressings
Ferris Mfg. Corp., Burr Ridge, IL 60527

RATIONALE

Polymeric membrane dressings are proven to provide significant wound pain relief by inhibiting nociceptor activity at the wound site. They contain a gentle cleanser, so after initial debridement and/or cleaning no manual wound cleansing is usually needed, allowing for less disruption of the new growth at the wound bed and very quick and easy dressing changes. The clinician's previous experience with polymeric membrane dressings on skin tears led to the conclusion that, "it helps heal them quickly, painlessly and does help the bruising go away."

Due to the patient's debilitated state and co-morbidities, infection was a serious concern. Silver polymeric membrane dressings have been found effective against: *Staphylococcus aureus* (MRSA and Non-MRSA), *Enterococcus faecalis* (VRE), *Klebsiella pneumoniae*, *Pseudomonas aeruginosa* and *Candida albicans*. Recently, several other modern silver dressings were found to be severely cytotoxic in vivo, but cells in contact with silver polymeric membrane dressings proliferated. This further affirms the author's decision to use silver polymeric membrane dressings.

METHODOLOGY

The dried blood was cleansed from the wound gently with sterile water. Initially, the periwound area was swollen with induration and the wound drained a moderate amount of purulent light yellow exudate. So, a silver polymeric membrane dressing was applied and changed daily for the first week of treatment. When the exudate was no longer purulent, standard polymeric membrane dressings were used instead. These were initially changed daily, then every-other-day, every three days and finally every five days. Polymeric membrane dressings were used to complete wound closure. The wound bled often during the first two weeks, so it was cleansed daily then, but it was not cleansed throughout the treatment as would have been necessary with other dressings.

OBJECTIVES

1. Review evidence for the use of polymeric membrane dressings on skin tears.
2. Discuss the benefits of using polymeric membrane dressings, which have been shown to help reduce wound pain not only during dressing changes, but also while the dressing is in place.
3. Consider the advantages of using polymeric membrane dressings in terms of passive continuous cleansing of the wound bed, which often eliminates painful and time-consuming wound cleansing during dressing changes.

RESULTS

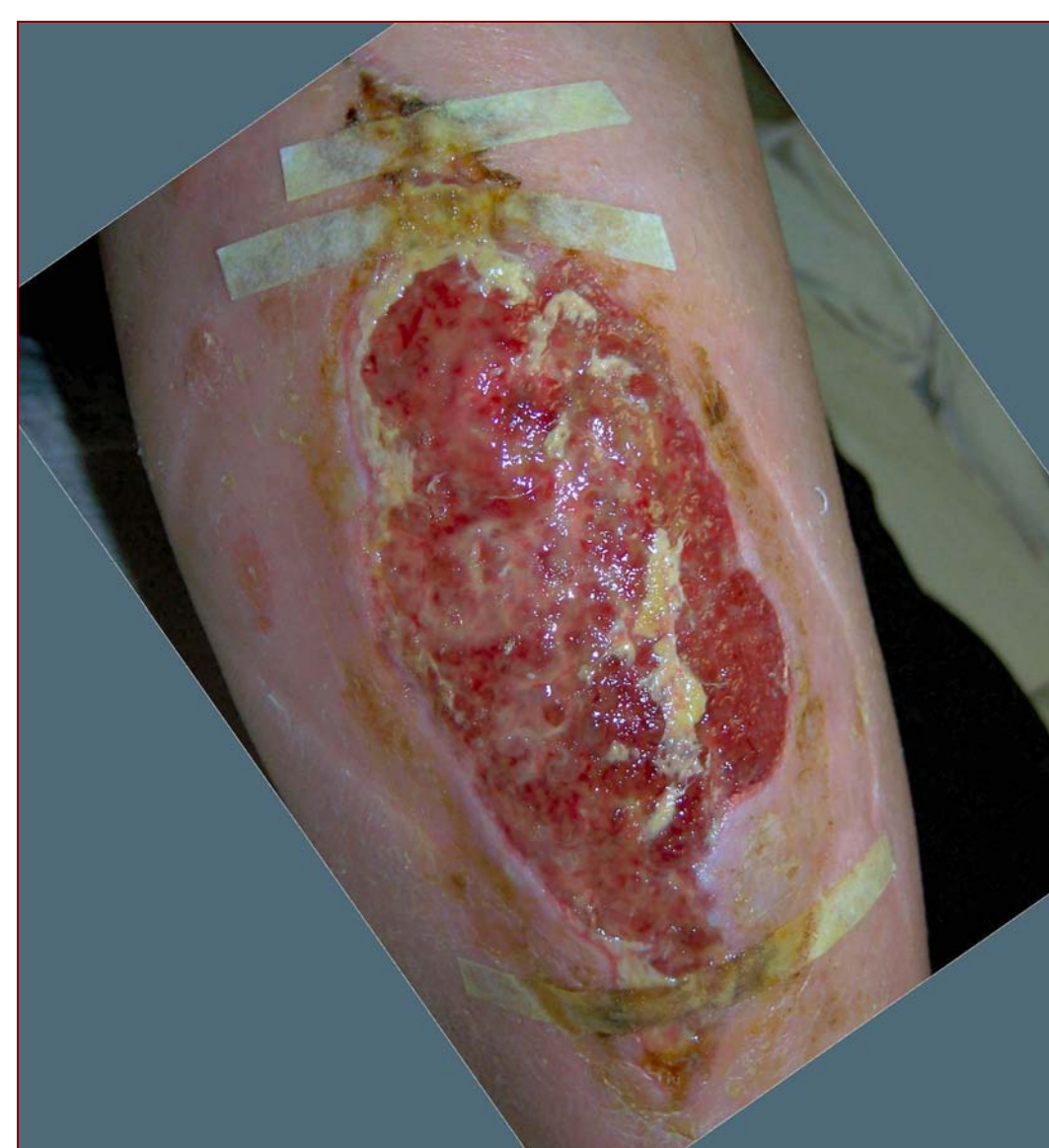
Granulation tissue formed quickly, with complete wound closure in only three months. The patient did not have wound pain at any time after the first day, despite the depth of the wound. Slough was drawn into the dressing, revealing a clean wound bed at dressing changes. So, after the first two weeks, manual wound bed cleansing was not performed.

CONCLUSION

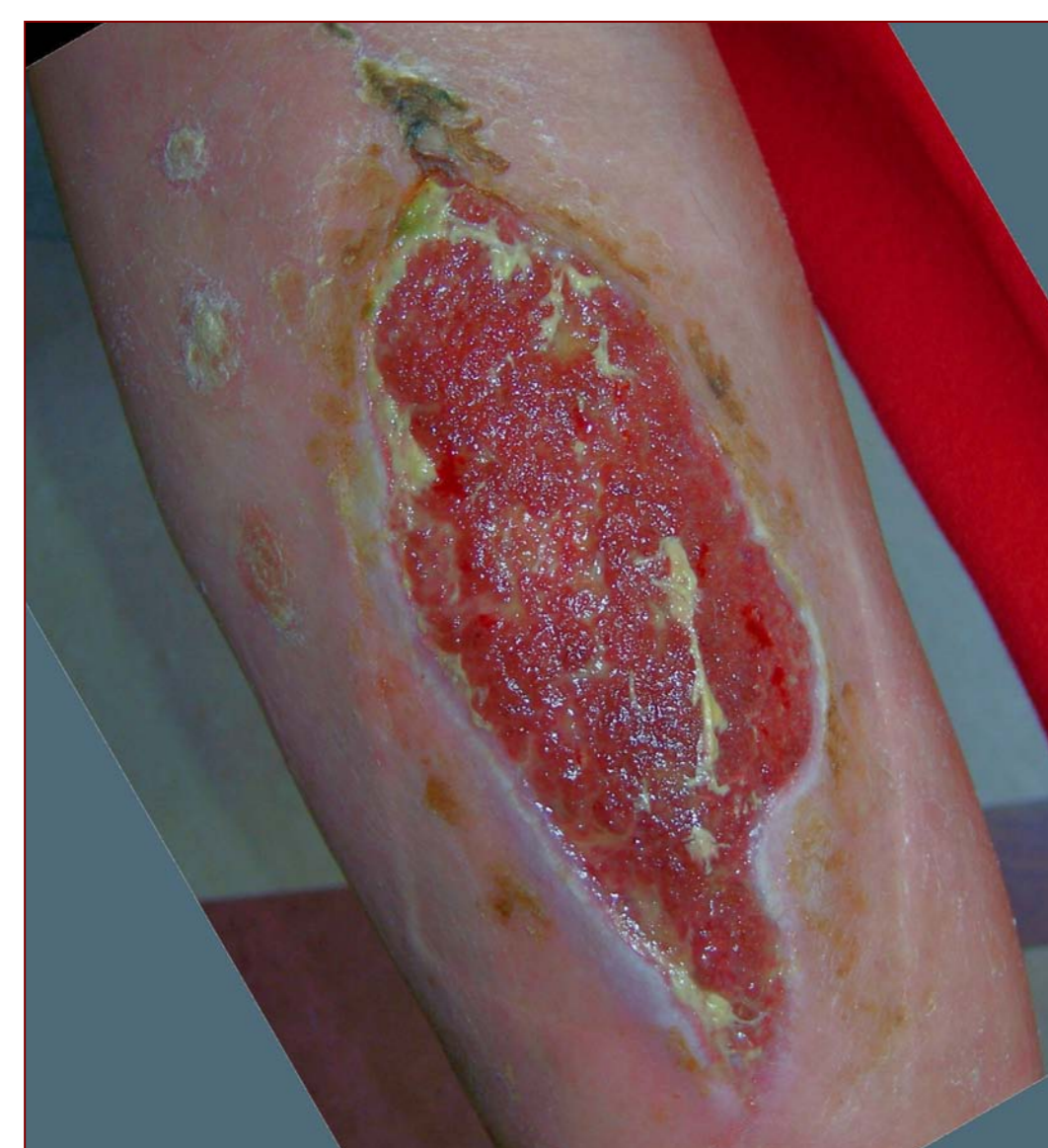
The polymeric membrane dressings were effective and easy to apply. After the initial cleansing and dressing of the wound by the wound team, the patient remained completely free from wound pain. The wound cleaned up quickly and healed in only three months, much faster than the clinician would have expected when using other dressings.

BIBLIOGRAPHY

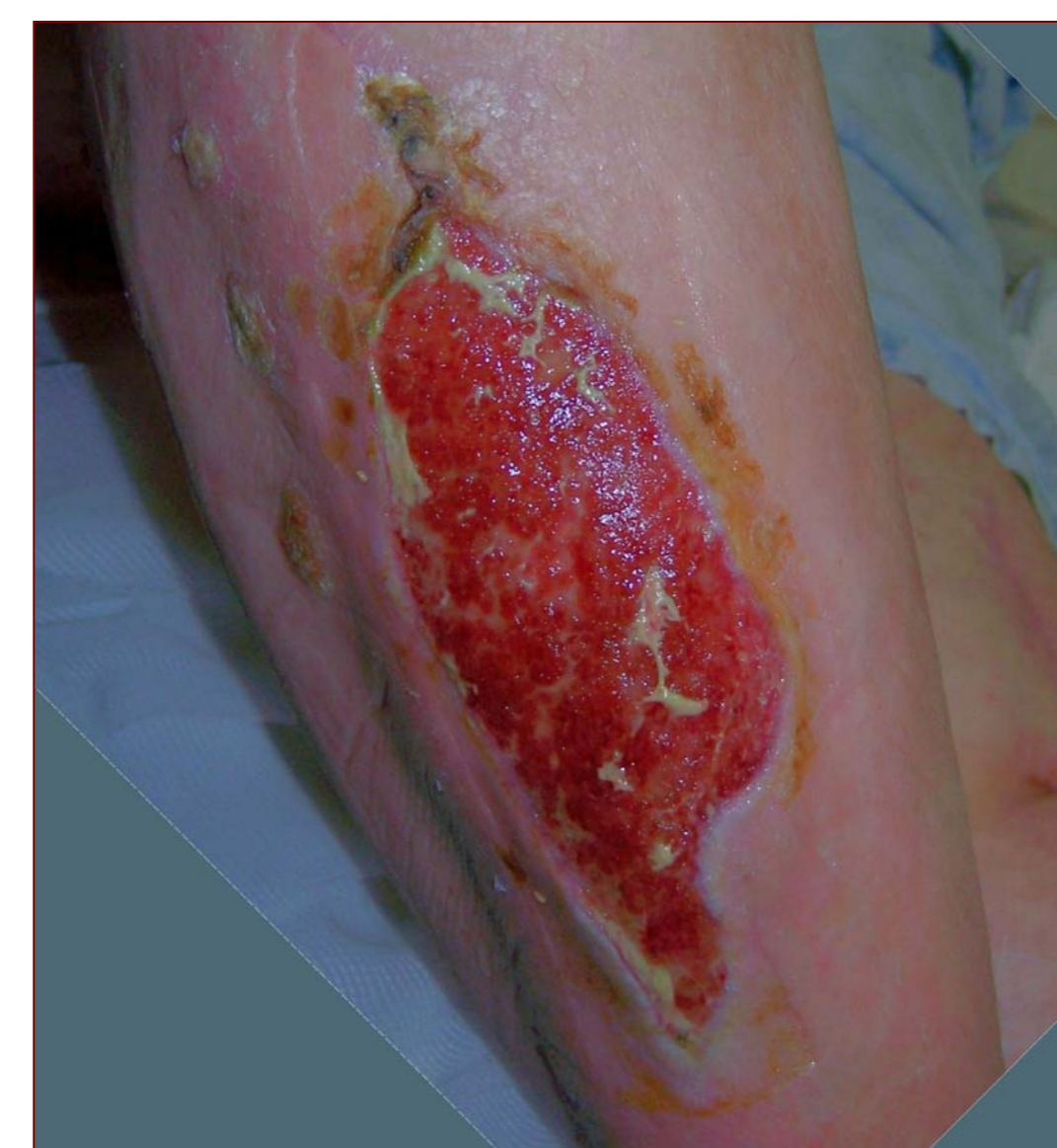1. Fleck, CA. Managing wound pain: today and in the future. *Advances in Skin and Wound care* 2007;20:3,138-145.
2. Hess CT. *Wound Care Clinical Guide*. Lippincott Williams & Wilkins. Ambler, PA. 2005; 275-6.
3. Fowler E, Papen JC. Clinical evaluation of a polymeric membrane dressing in the treatment of dermal ulcers. *Ostomy/Wound Manage*. 1991;35:35-38,40-44.
4. Burd A, Kwok CH, Hung SC, Chan HS, Gu H, Lam WK, Huang L. A comparative study of the cytotoxicity of silver-based dressings in monolayer cell, tissue explant, and animal models. *Wound Repair and Regeneration* 2007 15:94-104.
5. Beitz AJ, Newman A, Kahn AR, Ruggles T, Eikmeier L. A polymeric membrane dressing with antinociceptive properties: analysis with a rodent model of stab wound secondary hyperalgesia. *J Pain*. 2004 Feb;5(1):38-47.



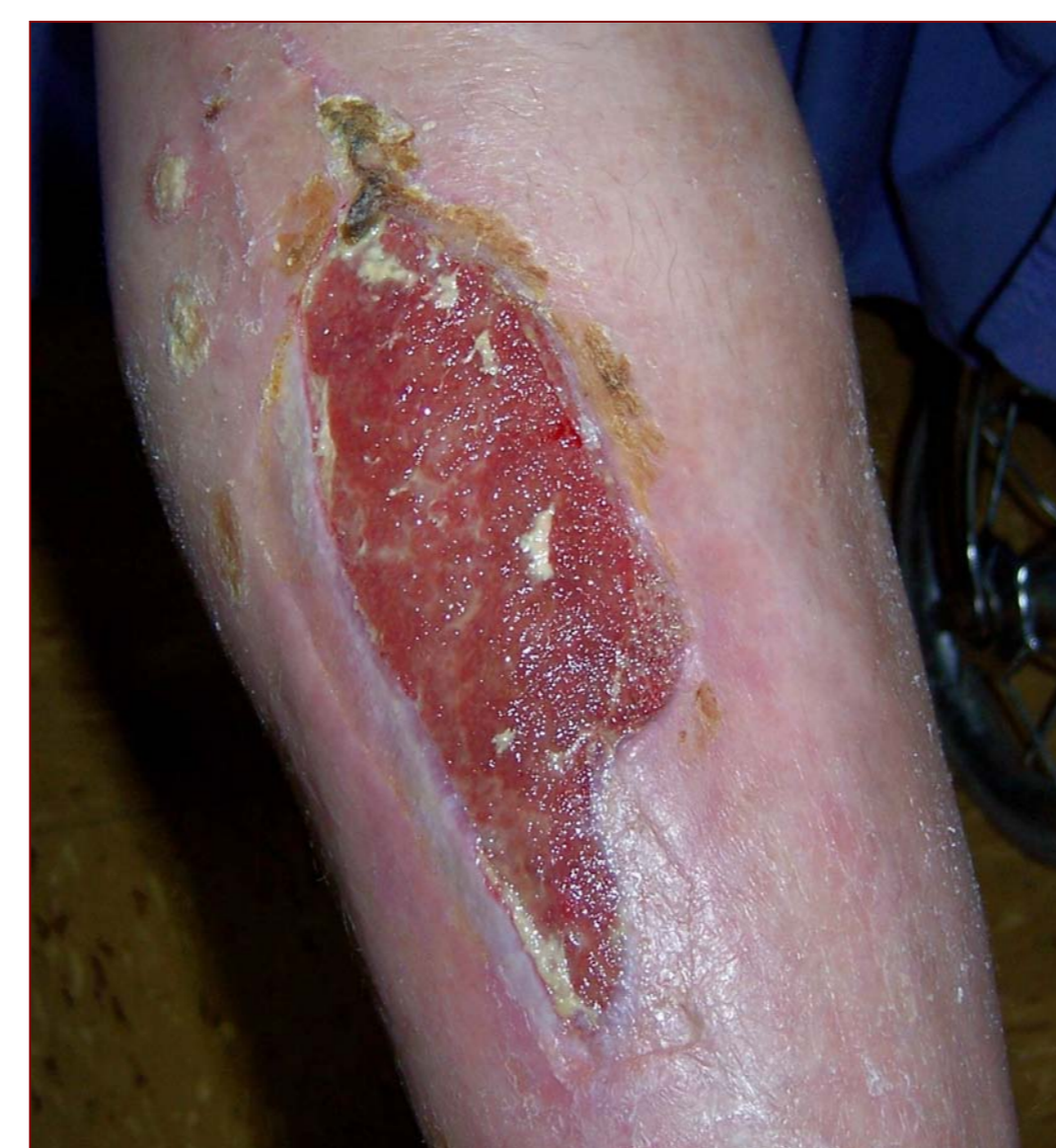10 Jan 2006: 13 cm x 5 cm x 0.1 cm
Purulent light yellow exudate. Daily silver polymeric membrane dressings initiated. No wound pain after the first day of treatment.



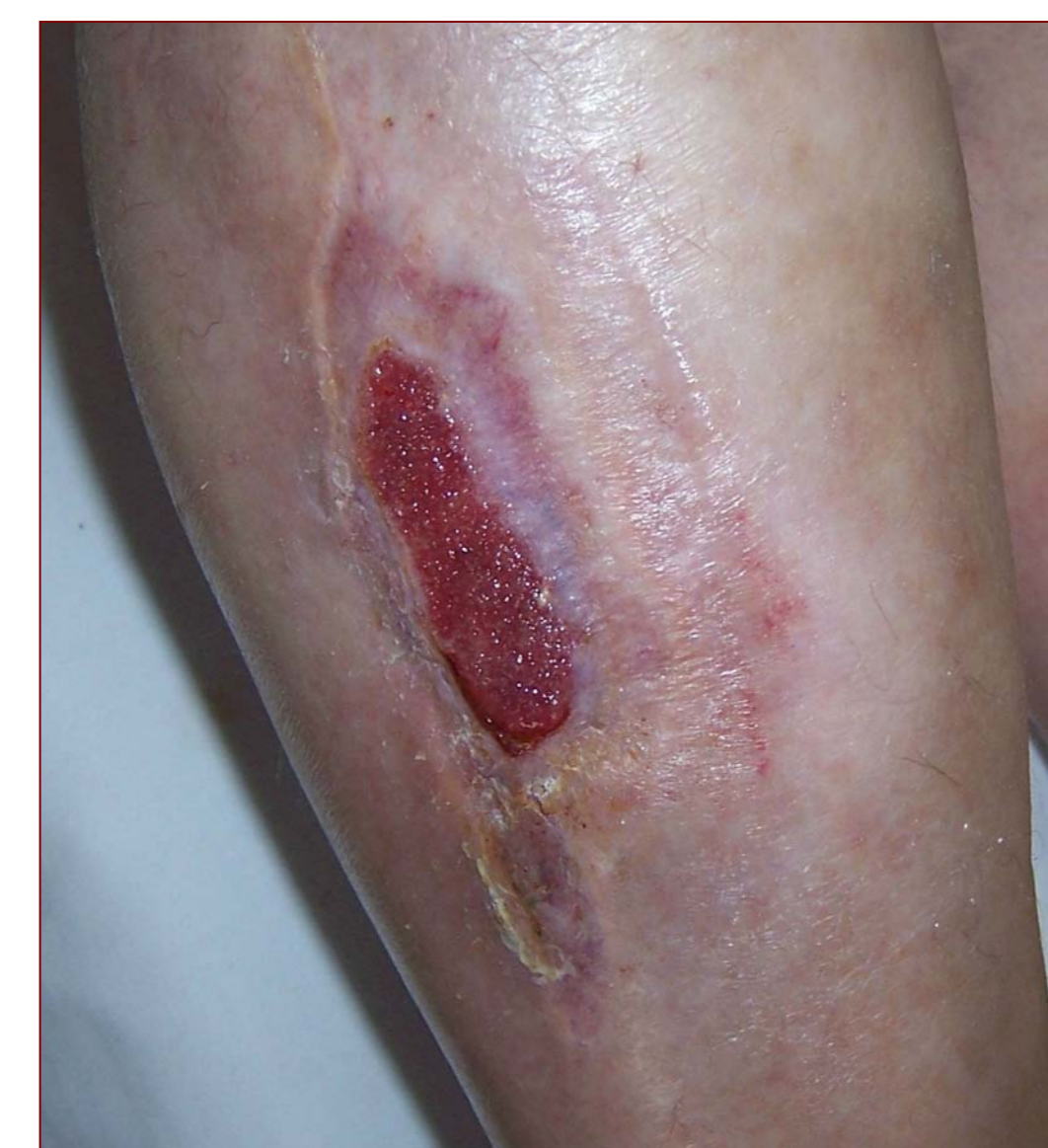17 Jan 2006: 11.5 cm x 5 cm
Serous exudate. Changed to standard polymeric membrane dressings. The patient still states she has no wound pain at all.



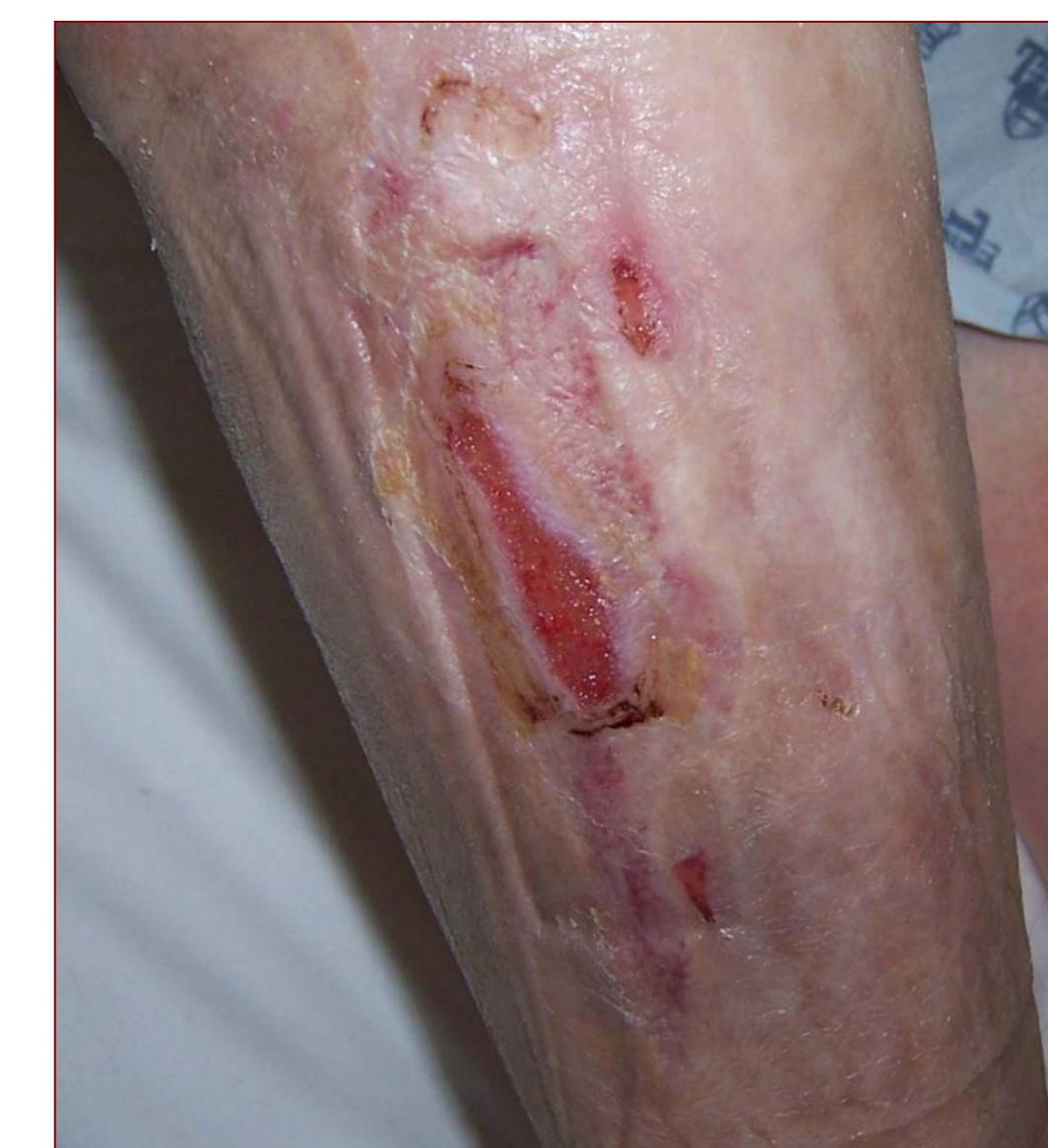30 Jan 2006: 10 cm x 4.1 cm
No wound cleansing needed for past week. Continuing polymeric membrane dressings.



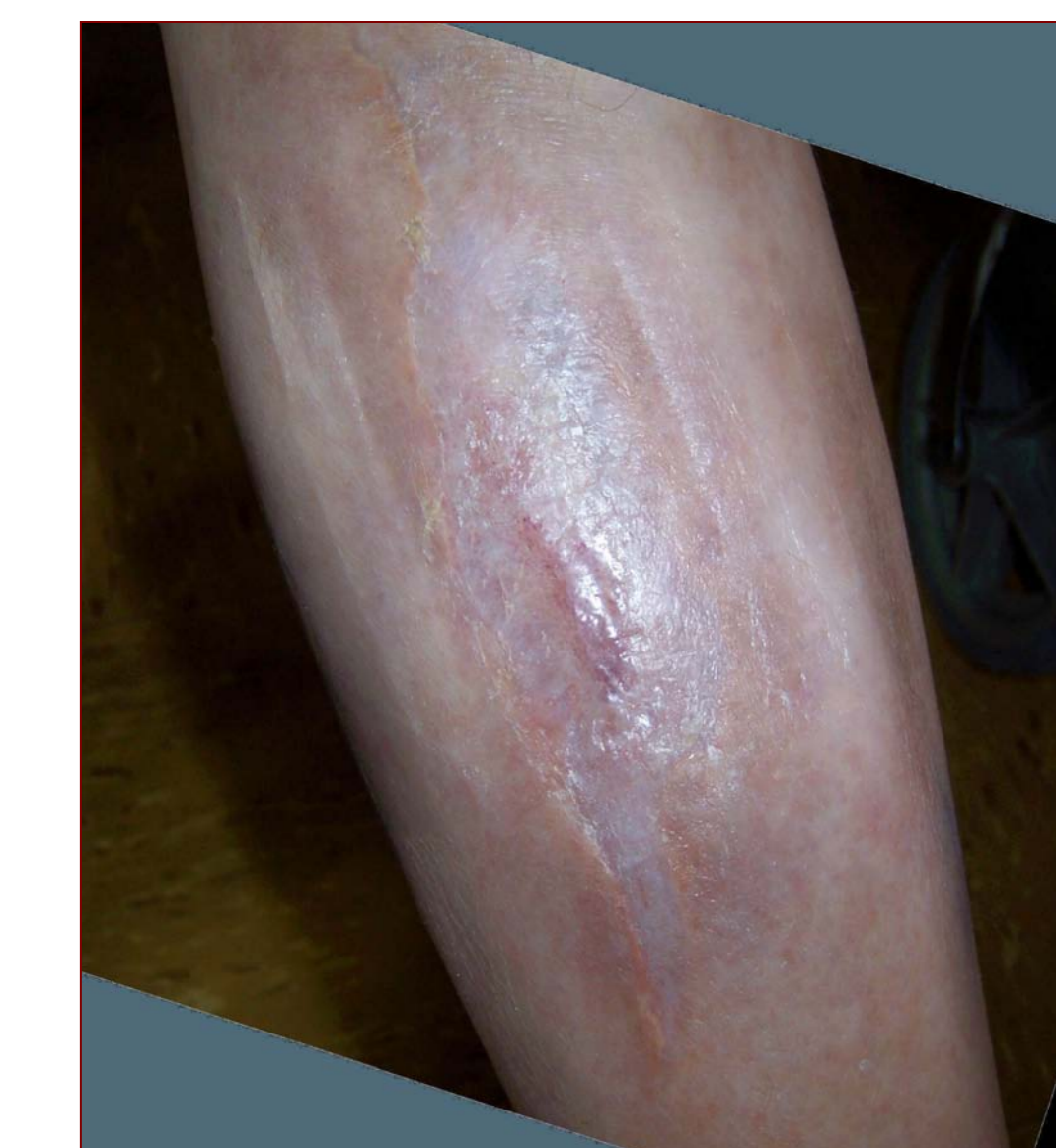7 Feb 2006: 9.8 cm x 3.1 cm
95% granulation tissue. Still no pain at dressing changes or while dressing is in place.



21 Feb 2006: 5.6 cm x 2.2 cm
100% granulation tissue. Dressings are now being changed every other day.



21 Mar 2006: 3 cm x 0.9 cm
100% granulation tissue. Dressings are now being changed every third day.



4 April 2006: Closed. No wound pain during the entire time of treatment (after day 1) with polymeric membrane dressings.