

# Heparan Sulfate Proteoglycan Mimetics Promote Tissue Regeneration: An Overview

Johan van Neck<sup>1</sup>, Bastiaan Tuk<sup>1</sup>, Denis Barritault<sup>2</sup> and Miao Tong<sup>1</sup>

<sup>1</sup>*Department of Plastic and Reconstructive Surgery, Erasmus MC, University Medical Center, Rotterdam,*

<sup>2</sup>*Laboratoire CRRET, Université Paris Est, Créteil,*

<sup>1</sup>*The Netherlands*

<sup>2</sup>*France*

## 1. Introduction

### 1.1 Normal wound healing

Wound healing is a complex and dynamic process that requires the coordinated completion of a variety of cellular activities, including phagocytosis, chemotaxis, mitogenesis, and synthesis of components of the extracellular matrix. These activities occur in a cascade that correlates with the appearance of multiple cell types and is regulated by soluble mediators such as growth factors and cytokines. In the wound healing process, three phases can be recognized: hemostasis and inflammation, proliferation, and tissue remodeling. These three phases are distinct but overlap in time (Singer and Clark 1999; Diegelmann and Evans 2004; Broughton, Janis et al. 2006).

### 1.2 Hemostasis and inflammation

Hemostasis and inflammation occur immediately after tissue injury. They prevent ongoing blood and fluid loss and establish an immune barrier against invading micro-organisms. Hemostasis is achieved by vasoconstriction and blood clotting. Platelets initiate the clotting cascade, initially by forming a platelet plug. This platelet plug is followed by a fibrin clot, which provides a provisional matrix scaffold for cell migration. Platelets also secrete a variety of growth factors and cytokines such as fibroblast growth factor (FGF), epidermal growth factor (EGF), platelet derived growth factor (PDGF), transforming growth factor beta (TGF- $\beta$ ), vascular endothelial growth factor (VEGF) and epidermal growth factor (EGF). These growth factors are located in the fibrin clot and act as promoters in the wound healing process by recruiting inflammatory cells to the wound site and initiating angiogenesis (Martin 1997).

Once the bleeding is controlled, inflammatory cells migrate into the wound area. This is the start of the inflammatory phase, which is characterized by the sequential infiltration of neutrophils, macrophages, and lymphocytes (Broughton, Janis et al. 2006).

Neutrophils are recruited to the wound site within 24-36 h after wounding. They are attracted by the growth factors released by degranulating platelets and by the products of

complement activation and bacteria degradation (Gurtner, Werner et al. 2008). Infiltrating neutrophils phagocytose contaminating bacteria and release pro-inflammatory cytokines to activate local fibroblasts and keratinocytes (Hubner, Brauchle et al. 1996). Within a few days after injury, neutrophils are extruded as eschar or as a result of apoptosis and finally are replaced by macrophages (Witte and Barbul 1997).

Macrophages migrate into the wound within two or four days after injury and become the predominant cell type. Macrophages are derived from blood monocytes and act as the “orchestra conductor” of wound healing (Lawrence and Diegelmann 1994). In the early stages of wound healing, macrophages phagocytose the remaining debris, bacteria, and apoptotic cells, including neutrophils, thus paving the way for the resolution of inflammation (Guo and Dipietro 2010). Macrophages also secrete a battery of cytokines (e.g., tumor necrosis factor alpha (TNF- $\alpha$ ), interleukin-1 (IL-1), and IL-6), growth factors (e.g., VEGF, FGF, PDGF, TGF- $\beta$ , and EGF), and different types of metalloproteinases that degrade the collagen matrix (Henry and Garner 2003). This way macrophages influence cellular recruitment, cellular activation, angiogenesis, fibroplasia and also regulate the synthesis and formation of the provisional extracellular matrix, which serves as a scaffold for dermal regeneration and epidermal proliferation.

Subsequently, T-lymphocytes enter the wound area and peak during the late-proliferative/early remodeling phase. T-lymphocytes likely are involved in controlling the proliferation phase of wound healing. However, their exact role is not completely understood and is a current area of intensive investigation (Broughton, Janis et al. 2006; Guo and Dipietro 2010).

### **1.3 Proliferation**

The proliferation phase follows and partly overlaps the inflammatory phase. The proliferation phase starts on the third day after injury and lasts for about 2-4 weeks. This phase is characterized by epithelial proliferation and migration over a provisional matrix within the wound (reepithelialization), fibroblast migration, and formation of granulation tissue. With the progression of proliferation, the provisional fibrin/fibronectin based provisional matrix is replaced by newly formed granulation tissue (Broughton, Janis et al. 2006; Velnar, Bailey et al. 2009).

#### **1.3.1 Reepithelialization**

Reepithelialization of the wound area starts within hours after injury. Epidermal cells at the wound margin undergo a marked phenotypic alteration and begin to migrate into the wound area (Paladini, Takahashi et al. 1996). Migrating epidermal cells dissect under the fibrin clot across the wound, separating the desiccated eschar from viable tissue. Epidermal cells behind the leading migrating edge proliferate, mature and finally restore the barrier function of the epithelium. The stimulus for the migration and proliferation of epidermal cells during reepithelialization has not been clearly determined, but several possibilities are well documented. The absence of neighbor cells at the margin of wound (i.e., the “free edge” effect) may induce both migration and proliferation of epidermal cells. Local release of growth factors and cytokines also stimulate these processes. The initial stimulus for proliferation and migration of epidermal cells includes the action of EGF, TGF- $\alpha$ , IL-1 and

TNF- $\alpha$ , which are released by activated platelets and/or macrophages (Grotendorst, Soma et al. 1989; Lawrence and Diegelmann 1994). Keratinocyte growth factors (KGFs) and IL-6, which are released by fibroblasts, play a role in attracting neighboring keratinocytes to migrate, proliferate, and differentiate into epithelium (Smola, Thiekotter et al. 1993; Xia, Zhao et al. 1999).

### 1.3.2 Fibroblast migration

Fibroblast migration occurs two to four days after injury. Fibroblasts are attracted to the wound area by a number of factors, such as PDGF and TGF- $\beta$  (Goldman 2004), and dominate the wound cell population in the first week. Within the wound area, fibroblasts proliferate and produce multiple structural molecules, including fibrin, fibronectin, glycosaminoglycans (GAGs), later followed by collagen (Witte and Barbul 1997; Robson, Steed et al. 2001; Ramasastry 2005). Together, these components construct the fibrin/fibronectin based provisional matrix (Clark, Lanigan et al. 1982), which contributes to the formation of granulation tissue.

### 1.3.3 Granulation tissue formation

Granulation tissue formation starts three to five days after injury and is characterized by angiogenesis. The numerous angiogenic factors that are secreted during the hemostatic phase, such as FGF, VEGF, TGF- $\beta$ , and PDGF, promote angiogenesis (Servold 1991). Four steps can be recognized in this process: (1) proteolytic degradation of the basement membrane of the parent vessels, allowing the formation of “capillary sprouts”; (2) migration of the endothelial cells towards the angiogenic stimulus; (3) proliferation; (4) maturation and remodeling of endothelial cells into capillary tubes (Velnar, Bailey et al. 2009). Capillary sprouts invade the fibrin/fibronectin based provisional matrix within a few days and organize into a dense microvascular network. This is so called vascularized stroma, together with macrophages and proliferating fibroblasts, constitute the acute granulation tissue that replaces the fibrin/fibronectin based provisional matrix (Witte and Barbul 1997; Baum and Arpey 2005). With collagen accumulation, angiogenesis ceases and the density of the microvascular network diminishes. When homeostasis between collagen synthesis and degradation is achieved, tissue remodeling begins.

## 1.4 Tissue remodeling

Tissue remodeling phase is the final phase of wound healing. It starts one week after injury and lasts over a year or more. The main feature of this phase is the deposition of collagen in an organized network. During this phase, all short term events that were activated after injury cease: most macrophages, endothelial cells, fibroblasts, and myofibroblasts undergo apoptosis or exit from the wound. They leave a mass that consists mostly of collagen and other matrix proteins. Without an increase in collagen content, this largely acellular matrix subsequently is reorganized from a disorganized, mainly type III collagen fibers containing temporary matrix, into a lattice structure which is predominantly composed of type I collagen (Madden and Peacock 1968; Gurtner, Werner et al. 2008). A process that is dependent on collagen synthesis, which in part is the net result of the interaction between matrix metalloproteinases and tissue inhibitors of

metalloproteinases (Madlener, Parks et al. 1998). During this phase, the wound progressively continues to increase in tensile strength. Nevertheless, wounds never regain the original strength. At maximal strength, healed wounds are 80% as strong as normal skin (Madden and Peacock 1968).

## 2. Impaired wound healing

Impaired healing wounds generally failed to progress through the normal stages of wound healing. Impaired healing wounds can be arrested in any of the different healing stages, however, frequently enter a state of pathologic inflammation. As a result, the wounds cannot be repaired in an orderly and timely manner, subsequently resulting in poor anatomical and functional outcome (Lazarus, Cooper et al. 1994). Both acute wounds and chronic wounds can exhibit impaired healing.

### 2.1 Factors affecting wound healing

Wound healing can be impaired by multiple factors in any of the healing phases. These factors are categorized into local and systemic factors. Local factors are those that directly influence the characteristics of the wound. Systemic factors concern the overall health or disease state of the individual which affects the ability to heal (Table 1). However, these factors often are interrelated so their influences are not mutually exclusive. Single or multiple factors may, therefore, play a role in any one or more individual phases, contributing to the overall outcome of the healing process (Guo and Dipietro 2010).

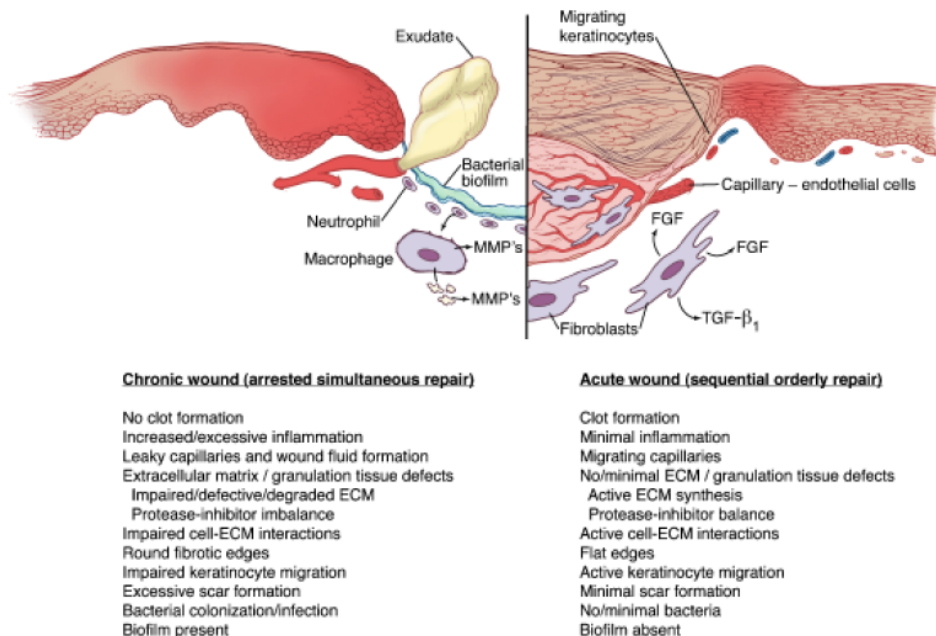
Local Factors	Systemic Factors
Infection	Age
Tissue maceration	Sex hormones
Foreign bodies	Obesity
Ischemia	Stress
Venous insufficiency	Diseases: diabetes , artery disease, peripheral vascular disease
Desiccation	Immunocompromised conditions: AIDS, radiation therapy, chemotherapy
Necrosis	Congenital healing disorders: epidermolysis bullosa, Ehlers-Danlos syndrome, Marfan's syndrome
Pressure	Alcoholism
Trauma	Smoking
Edema	Distant cancer
Local cancer	Uremia
Radiation	Nutritional deficiencies
Toxins	
Iatrogenic factors	

Table 1. Factors that affect wound healing.

In view of the large variety of factors that can be involved in impaired healing wounds, the types of chronic wounds are numerous. However, the most common chronic wounds are pressure ulcers, diabetic ulcers, and venous ulcers. Together, they constitute approximately 70% of all chronic wounds (Eaglstein and Falanga 1997).

## 2.2 Pathophysiology of impaired wounds

The differences in physiology and healing dynamics between acute and chronic wounds are numerous (Figure 1) (Schultz and Wysocki 2009). Excessive inflammation and abnormalities in cell-extracellular matrix interaction are considered important mechanisms responsible for the failure of chronic wounds to heal (Eming, Krieg et al. 2007; Menke, Ward et al. 2007; Schultz and Wysocki 2009).



Copyright 2009 by the Wound Healing Society

Fig. 1. Comparison of a chronic wound in which repair is arrested and an acute wound in which repair proceeds in an orderly, sequential fashion. Differences between these wounds are seen in clot formation, inflammation, capillary migration, granulation tissue, extracellular matrix, keratinocyte migration, scar formation, bacterial colonization/infection, and biofilm formation (Schultz and Wysocki 2009).

Impaired wounds exhibit an out-of-control prolonged inflammatory response that is self-sustaining (Menke, Ward et al. 2007). An over-abundant neutrophil infiltration is responsible for this chronic inflammation (Diegelmann 2003; Diegelmann and Evans 2004). Neutrophils release significant amounts of enzymes such as metalloproteinases (Yager, Zhang et al. 1996; Nwomeh, Liang et al. 1998; Nwomeh, Liang et al. 1999; Lobmann, Ambrosch et al. 2002), which are not balanced by their respective inhibitors. As a result, the balance between matrix degradation and synthesis shifts towards degradation (Bullen, Longaker et al. 1995). In addition, neutrophils release elastase, an enzyme that is capable to destroy growth factors such as PDGF and TGF- $\beta$  (Yager, Zhang et al. 1996). This prolonged

inflammatory environment also contains excessive reactive oxygen species that further damage cells, growth factors and healing tissues (Wenk, Foitzik et al. 2001). Abnormalities in extracellular matrix - growth factor interactions characterize impaired wound healing (Schultz and Wysocki 2009). Impaired wounds are difficult to heal until the delayed inflammation is reduced and the interactions between extracellular matrix and growth factors are restored. Wound treatment strategies, with a focus on regulating these disrupted interactions, may benefit the treatment of impaired wound healing.

### 3. 'Standard' management options for wounds

The final goal of any wound management is to achieve wound healing. In the eyes of a cell biologist, these strategies might be seen as attempts to assist the injured tissue in recreating an extracellular matrix and cellular content, to enable tissue regeneration. In a somewhat simplistic view, most of the current routine clinical strategies to improve wound healing, therefore, can be classified into one or more of the categories that are depicted in Table 2.

	TREATMENT / STRATEGY	BENEFIT TO WOUND HEALING	LITERATURE (REVIEWS)
1.	Debridement (e.g. surgical, enzymatic, chemical)	Bring the wound edges into viable tissue in order to allow cells to deposit the right extracellular matrix needed for their migration and differentiation	(Attinger and Bulan 2001; Hess and Kirsner 2003)
2.	Moisture management	Create an environment that assists in propagating cell migration into the wound area	(Okan, Woo et al. 2007; Korting, Schollmann et al. 2011)
3.	Exudate management (e.g. by the application of foams, sponges or vacuum therapy)	Draining the wound fluid to clear extracellular matrix degrading enzymes and bacterial toxins	(Vowden and Vowden 2003)
4.	Local infection management	Create a sterile environment by clearing the wound from bacteria and secreted harmful substances, followed by creating a bacterial balance	(Fung, Chang et al. 2003)
5.	Inflammation management	Reduce the severity and duration of the immune reaction, to limit the production of soluble growth factors by immune cells that attract infiltrating, scar tissue producing, fibroblasts	(Nathan 2002; Diegelmann and Evans 2004)
6.	Growth factor management	Replenish the wound area, extracellular matrix and its cellular components with growth factors	(Krishnamoorthy, Morris et al. 2001; Barrientos, Stojadinovic et al. 2008)

Table 2. Cell biological effects of clinical treatment modalities

## 4. Advanced treatment options for wounds

Healing-arrested (chronic) wounds seriously lower the patient's quality of life and their treatments are extremely resource consuming. In the USA the costs related to chronic wounds are estimated over \$25 billion a year (Fan, Tang et al. 2011). In the European Union the costs related to pressure ulcers and venous ulcers are estimated around €20 billion per year. The severity of the problem, likely accompanied by the substantial financial gain that can be envisioned, triggers the development of a great variety of advanced treatment options. Many are described in literature, although mostly with minimal of proof of efficacy. Also many reviews exist on this topic (recent examples are e.g. (Rizzi, Upton et al. 2010; Fan, Tang et al. 2011)).

In the context of this chapter, only a limited discussion will follow that covers the following 'state of art' strategies:

1. Gene therapy
2. Platelet rich plasma therapy
3. Stem cell therapy
4. Biological dressings and skin substitutes

### 4.1 Gene therapy

Gene therapy clearly holds promise in the repair of soft tissue disorders like wounds (reviews on this topic e.g. Branski, Pereira et al. 2007; Eming, Krieg et al. 2007). Skin is easily accessible for genetic manipulations and has cellular constituents with a high turnover that can be an effective target for the transfer of genetic material. Especially a temporal delivery of growth factors by gene transfer may be helpful in transforming chronic wounds into healing wounds.

July 2011, gene therapy trials are listed at [www.clinicaltrials.gov](http://www.clinicaltrials.gov) concerning patients with diabetes-related, and lower limb ischemia-related ulcers. However, the application of genetic manipulation to the treatment of chronic wounds is still in its infancy.

### 4.2 Platelet rich plasma therapy

The alpha granules of platelets are rich in growth factors that are considered important for wound healing, amongst them EGF, FGF, PDGF, TGF- $\beta$  and VEGF. Therefore, the use of platelet rich plasma is considered superior to any single growth factor application. Topical use of platelet rich plasma is described over 2 decades in several case series. E.g. following a weekly application to patients with cutaneous wounds of variable origin, Crovetti et al. (2004) described a complete response in 9 of 24 patients and a partial response in an additional 9 patients (Crovetti, Martinelli et al. 2004). Schade and Roukis (2008) reported beneficial effects of platelet-rich plasma to the healing of split-thickness skin grafts (Schade and Roukis 2008). Kazakos et al. compared the use of platelet rich plasma versus conventional therapy in 59 patients suffering from acute trauma wounds. And reported a beneficial effect on wound size reduction and pain perception over a three week period (Kazakos, Lyras et al. 2009). Steed et al. (1992) performed a randomised controlled trial in 13 diabetic foot patients and observed, over a period of 15 weeks, increased healing in the platelet rich plasma group (Steed, Goslen et al. 1992).

July 2011, platelet rich plasma trials are listed at [www.clinicaltrials.gov](http://www.clinicaltrials.gov) concerning patients with burns, skin grafts, and leg ulcers.

### 4.3 Stem cell therapy

Literature on the use of bone marrow-derived stems cells, adipogenic stem cells and cutaneous mesenchymal stem cells, that are reported around the hair follicles, is manifold (reviews on this topic e.g. (Sellheyer and Krahl 2010; Wu, Zhao et al. 2010)). At the preclinical level, evidence in wound areas is accumulating regarding the differentiation of bone marrow-derived stem cells into dermal fibroblasts, fibrocytes and endothelial progenitor cells. However, at the clinical level, reports of sufficient quality are scarce. Dash et al. (2009) reported beneficial effects on ulcer healing and ulcer pain of the addition of bone marrow-derived mesenchymal stem cells to a total of 24 patients with lower limb non-healing ulcers that were randomly allocated to the placebo or stem cell therapy group (Dash, Dash et al. 2009). Walther et al. (2011) reported a pilot on the intraarterial administration of bone marrow derived mononuclear cells to patients with critical ischemia in a phase II randomised-start open label study (Walter, Krankenberg et al. 2011). Forty patients enrolled over a period of 3 years and a significantly improved ulcer healing and reduction of rest pain were found in the bone marrow group.

July 2011, over ten stem cell trials are listed at [www.clinicaltrials.gov](http://www.clinicaltrials.gov) concerning patients with burn, pressure, diabetes-related and lower limb ischemia-related ulcers.

### 4.4 Biological dressings and skin substitutes

The complexity of the skin: its cellular constitution, extracellular matrix characteristics and the many growth factors involved in maintaining functional skin layers, let alone their involvement in wound healing (Table 3), largely determined research efforts.

Reports on dermal replacement and dermal addition strategies are manifold (recent reviews on this topic e.g. (Rizzi, Upton et al. 2010; Fan, Tang et al. 2011)). Briefly, research efforts to establish novel treatments can be categorized in tissue engineered skin based therapies, growth-factor based therapies, extracellular matrix based therapies and combinations thereof.

Dermal replacements, e.g. to cover large ulcers or burn injuries, are described using autografts, allografts or tissue engineered skin substitutes. Over a dozen of tissue engineered dermal replacements are on the market (Rizzi, Upton et al. 2010).

Dermal addition strategies are described using collagen, chondroitin-6-sulfate and hyaluronic acid.

Growth factor addition into the wound bed aims to reestablish or accelerate the natural healing process of chronic and acute wounds. Predominantly via preclinical research efforts, with currently PDGF and bFGF on the clinical market (Rizzi, Upton et al. 2010).

Hodde and Johnson (2007) elaborate on the role of the extracellular matrix to stimulate, direct and coordinate healing by storing a variety of growth factors at physiological levels (Hodde and Johnson 2007).



Growth Factors	Cells	Acute Wound	Function	Chronic Wound
EGF	Platelets Macrophages Fibroblasts <sup>44,45</sup>	Increased levels <sup>46,47</sup>	Reepithelialization <sup>48</sup>	Decreased levels <sup>51</sup>
FGF-2	Keratinocytes Mast Cells Fibroblasts Endothelial cells Smooth muscle cells Chondrocytes <sup>58,75,76</sup>	Increased levels <sup>79,81</sup>	Granulation tissue formation Reepithelialization Matrix formation and remodeling <sup>77</sup>	Decreased levels <sup>52</sup>
TGF- $\beta$	Platelets Keratinocytes Macrophages Lymphocytes Fibroblasts <sup>92,93,96</sup>	Increased levels <sup>98</sup>	Inflammation Granulation tissue formation Reepithelialization Matrix formation and remodeling <sup>81,101,107</sup>	Decreased levels <sup>52</sup>
PDGF	Platelets Keratinocytes Macrophages Endothelial cells Fibroblasts <sup>53,140,141</sup>	Increased levels <sup>144</sup>	Inflammation Granulation tissue formation Reepithelialization Matrix formation and remodeling <sup>141,142,146,153</sup>	Decreased levels <sup>52</sup>
VEGF	Platelets Neutrophils Macrophages Endothelial cells Smooth muscle cells Fibroblasts <sup>69,160-164</sup>	Increased levels <sup>185</sup>	Granulation tissue formation <sup>177,180</sup>	Decreased levels <sup>52</sup>
IL-1	Neutrophils Monocytes Macrophages Keratinocytes <sup>13,60</sup>	Increased levels <sup>242</sup>	Inflammation Reepithelialization <sup>244</sup>	Increased levels <sup>51</sup>
IL-6	Neutrophils Macrophages <sup>245</sup>	Increased levels <sup>245</sup>	Inflammation Reepithelialization <sup>77,78</sup>	Increased levels <sup>245</sup>
TNF- $\alpha$	Neutrophils Macrophages <sup>60,242</sup>	Increased levels <sup>51</sup>	Inflammation Reepithelialization <sup>51</sup>	Increased levels <sup>51</sup>

Copyright 2008 by the Wound Healing Society

Table 3. Major growth factors and cytokines that participate in wound healing with cell types and their respective roles in both acute and chronic wounds are listed (Barrientos, Stojadinovic et al. 2008). Reference numbers refer to their original publication.

#### 4.5 Concerns about biological products based treatment

Although some of the new techniques mentioned above are promising in small-scale trials, only a minority are evidence based. Important issues that need to be addressed:

- Lack of large double blinded randomised controlled preclinical trials.  
The current evidence for many biological products based treatment is generally based on non-randomised prospective trials, small-scale trials, or single case studies.
- Lack of sufficient evidence of efficacy.  
The efficacy of most biological products is currently not approved in large trials.

- Lack of cost-effectiveness.  
As most biological products are expensive the lack of cost-effectiveness studies may limit their widespread application.
- Confirmation of safety.  
Many sources of the biological products are from human or animal tissues, which hold the, theoretical, risk of transmitting infection and diseases.

Both standard and advanced wound healing strategies frequently aim to recreate a bioactive extracellular matrix. In the remainder of this overview, the focus is on the constituents of the extracellular matrix that secures the stability of growth factors in the matrix. Their role in enabling tissue homeostasis and tissue regeneration is discussed.

## 5. Tissue homeostasis and the extracellular matrix

Proteoglycans consist of a core protein with one or more covalently linked glycosaminoglycan chains. Glycosaminoglycans are long chain, high molecular weight carbohydrates. Some of these are sulfated (chondroitin sulfate, dermatan sulfate and heparan sulfate), other are non-sulfated (hyaluronic acid) (McGrath and Eady, 1997). When combined with water glycosaminoglycans form a gel and contribute to the viscoelastic properties of connective tissue. In addition to this mechanical role, proteoglycans may also have regulatory roles of which heparan sulfate is a prominent example.

Heparan sulfates are linear polysaccharides with variable degrees of sulfation, N-sulfation and N-acetylation (Dreyfuss, Regatieri et al. 2009) (Tumova, Woods et al. 2000). Heparan sulfates are widely spread throughout the animal kingdom ranging from invertebrates to mammals. In organs and tissues, they are a ubiquitous part of the extracellular matrix since many of the matrix scaffold proteins, such as collagens, fibronectin and laminin, possess heparan sulfate binding sites (Dreyfuss, Regatieri et al. 2009).

A large variety of proteins can bind heparan sulfates. Amongst these are cell surface proteins, extracellular matrix proteins, growth factors, cytokines, chemokines and morphogens. Heparan sulfates protect these proteins from degradation and secure their presence in the extracellular matrix. Due to the ubiquitous nature of heparan sulfates, the large amount of proteins they sequester and their fine-tuning effect in growth factor bioavailability, heparan sulfates participate in many physiological activities (e.g. cell proliferation, -migration, -differentiation and cell - cell interaction). And, therefore, play a prominent role in enabling tissue homeostasis, the process in which the tissues and organs pursue a constant internal environment and cellular composition (Watt and Fujiwara 2011).

However, the tissues response to 'stress', with stress being any form of integrity disturbance such as injury, inflammation, overuse, auto-immune response, is in releasing cleavage enzymes that degrade the proteins and glycosaminoglycans of the extracellular matrix, including heparan sulfates. Through this degradation, the orchestrating role of heparan sulfate in growth factor and cytokine sequestration is lost which ends tissue homeostasis (Barritault, Garcia-Filipe et al. 2010).

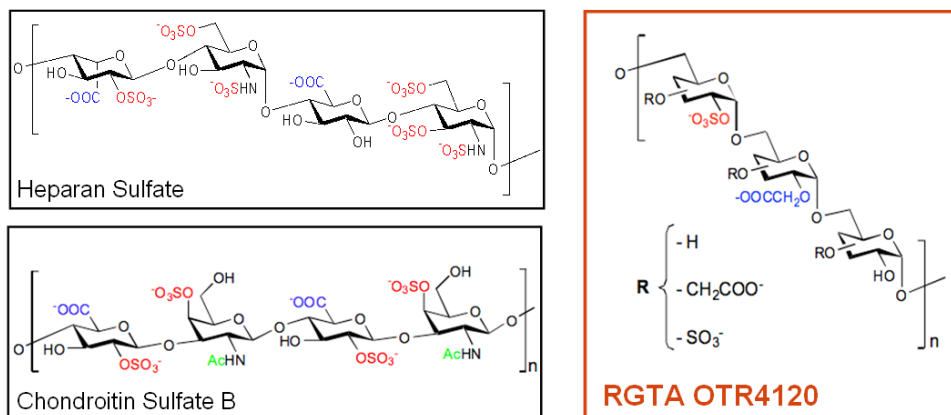
In wound healing, particularly in chronic wounds, dysregulation within the extracellular matrix and between cells and the extracellular matrix has gained importance (Cook, Davies

et al. 2000) and do therapeutic initiatives to restore the defective extracellular matrix and to reposition heparan sulfates (Agren and Werthen 2007; Gandhi and Mancera 2010).

## 6. ReGeneraTing Agents

### 6.1 Structure of RGTA

ReGeneraTing Agents (RGTA) are synthetic heparan sulfate mimics, resistant to glycanase digestion (Figure 2) (Barbier-Chassefiere, Garcia-Filipe et al. 2009; Ikeda, Charef et al. 2011).



Copyright 2011 by OTR3,

Fig. 2. RGTA OTR4120 is a structural analogue of glycosaminoglycans.

### 6.2 Working concept of RGTA / RGTA OTR4120

In wound areas, RGTA can replace heparan sulfates by binding the free heparan binding sites that become available following heparan sulfate degradation. This way, RGTA can regulate the bioavailability of the large variety of, locally synthesized, heparin binding proteins which allow the cellular tissue components to re-unfold their natural mechanism to achieve wound regeneration.

RGTA OTR4120 is a RGTA member specifically designed to treat chronic wounds and marketed as CACIPLIQ20® (OTR3, Paris, France). The affinity constant of RGTA OTR4120 towards the vacant heparan sulfate binding sites of the extracellular matrix proteins allows a tight binding. This makes a short-term exposure to RGTA OTR4120 sufficient. Once RGTA OTR4120 is in place in the matrix scaffold, the growth factors, cytokines and other heparin binding signaling peptides can be repositioned through RGTA OTR4120 binding in this restored micro-environment. In this way, RGTA OTR4120 is thought to offer a matrix therapy that restores the natural cellular microenvironment. This allows the endogenous signaling of cell communications needed for tissue regeneration to resume their original function thereby halting the self-perpetuating cycles, particularly in impaired healing wounds (Figure 3).

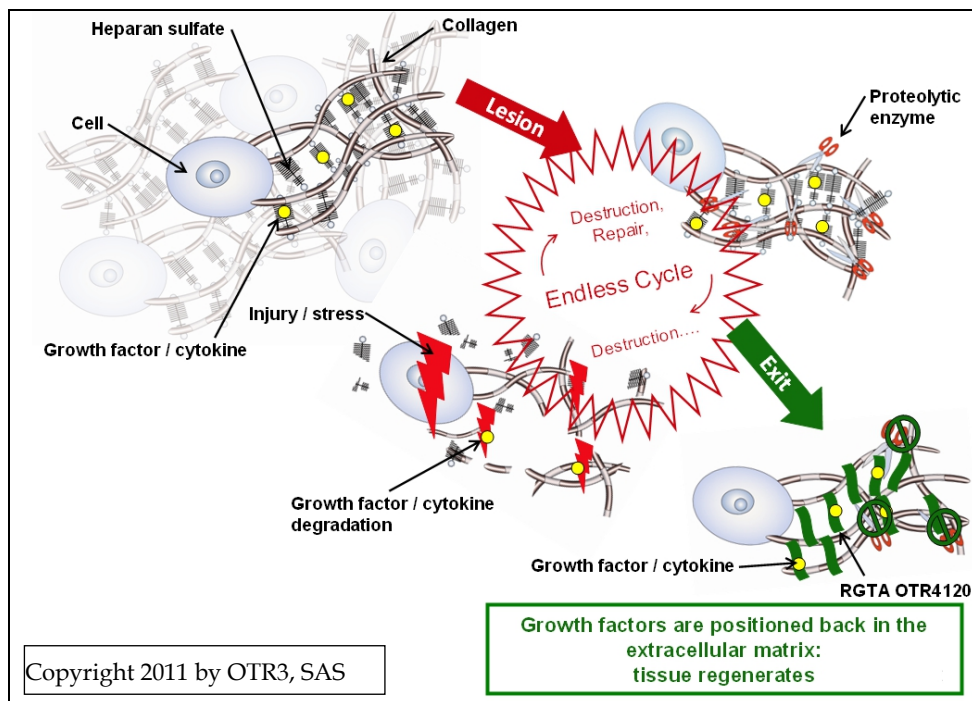


Fig. 3. RGTA OTR4120, mode of action.

### 6.3 Synthesis, dosing and timing

RGTA OTR4120 is prepared as a 85kD molecular weight fraction from T40 dextran by carboxymethylation and O-sulfonation (Barbier-Chassefiere, 2009; Ikeda, Charef et al. 2011). RGTA OTR4120 was proven completely resistant to digestion with multiple endoglycanases: heparanase, chondroitinase, hyaluronidase, dextranase (Table 4) (Ikeda, Charef et al. 2011).

Following a single i.v. injection in mice at a dose of 5 mg/kg the half life of unbound OTR4120 in plasma was less than 60 minutes. A i.p. bolus injection of 50 mg/kg in this same model created a peak plasma concentration of 88 µg/ml after 90 min (Charef, Papy-Garcia et al. 2010). A study on the acute and subacute toxicity, following i.p. administration, revealed no significant toxicological changes for doses up to 50 mg/kg (Charef, Tulliez et al. 2010). Injected doses used in a preclinical setting routinely are in the range of 1 - 2 mg/kg.

When topically administered on dermal wounds, a bell-shaped dose effect-curve was found for RGTA OTR4120 with an optimal dose of 0.1 mg/ml. A similar dose was found when treating skull defects (Colombier, Lafont et al. 1999) and parodontitis (Lallam-Laroye, Escartin et al. 2006).

RGTA OTR4120 is by itself a non acting molecule that enables the cascade of signals, that propagate wound regeneration, to resume with proper timing. However, the frequency of

applications should be timed as the number of free heparan binding sites are limited in wound tissue. RGTA OTR4120 administration every 3 days is proven sufficient to maintain the healing effect in the early phases. Excess RGTA OTR4120 may compete with sites on the matrix-bound RGTA for heparan binding growth factors. In following phases of wound regeneration a weekly administration also proved to be effective (Tong, Zbinden et al. 2008; Barbier-Chassefiere, Garcia-Filipe et al. 2009). No specific studies are reported to further optimize the timing of RGTA OTR4120 application.

Polysaccharide	Heparanases	Chondroitinase ABC	Hyaluronidase	Dextranase
HM4120	-	-	-	-
Heparin	+++	-	-	-
Heparan sulfate	+++	-	-	-
Chondroitin sulfate A	-	+++	+++	-
Hyaluronic acid	-	+++	+++	-
Dextran	-	-	-	+++

-: Undigested product, starting polysaccharide was recovered. +++: Completely digested polysaccharide.

Copyright 2010 Elsevier, Ltd.

Table 4. Polysaccharide digestion by endoglycanases. HM4120 = RGTA OTR4120 (Ikeda, Charef et al. 2011)

#### 6.4 Preclinical evidence for dermal RGTA OTR4120 actions

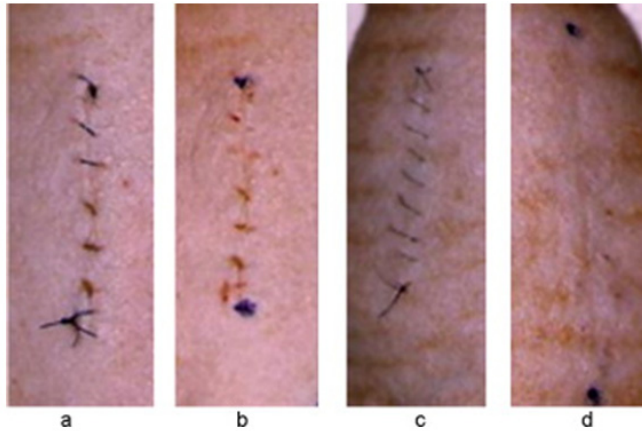
Effects of RGTA OTR4120 administration on tissue regeneration at the preclinical level are numerous and reported in over 70 scientific reports in close to 10 animal species. Dermal effects of RGTA OTR4120 administration are described in necrotic skin ulcers in mice (Barbier-Chassefiere, Garcia-Filipe et al. 2009), incisional dermal wounds in rats (Barritault, Garcia-Filipe et al. 2010), second degree burns in rats (Garcia-Filipe, Barbier-Chassefiere et al. 2007) (Zakine, Barbier et al. 2011), a rat surgical excision model (Tong, Zbinden et al. 2008; Tong, Tuk et al. 2009; Tong, Tuk et al. 2011) and in rat dermal ischemia ulcers (Tong, Tuk et al. 2011).

##### 6.4.1 Necrotic skin ulcers

Barbier-Chassefiere et al. (2009) determined the effects of RGTA OTR4120 in a necrotic skin ulcer model in mice following doxorubicin administration. In the short term, the necrotic surface area was found to be decreased by 40% with an almost 50% reduction in leukocyte count, as a measure for the strength of the inflammatory reaction. RGTA OTR4120 administration increased type I and decreased type III collagen which restoring these values to those found in normal skin (Barbier-Chassefiere, Garcia-Filipe et al. 2009). The results obtained from this ulcer model indicate that RGTA OTR4120 matrix therapy can initiate tissue regeneration. This finding illustrates that matrix contains the proper information to regenerate and confirms the central role for a good-quality extracellular matrix in tissue regeneration (Barbier-Chassefiere, Garcia-Filipe et al. 2009).

#### 6.4.2 Anti scar effects of RGTA

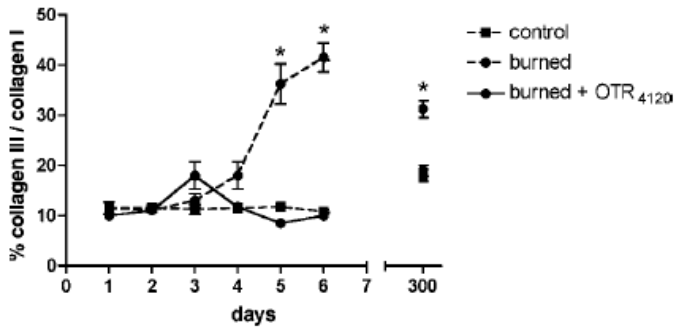
Barritault et al. (2010) described the effects of RGTA OTR4120 administration to a dermal incisional wound model in hairless rats (Barritault, Garcia-Filipe et al. 2010). Topical administration of RGTA OTR4120 to the incision at days 0, 3 and 6 revealed a scar free healing at day 10 whereas in the placebo control scar formation was clearly present (Figure 4).



Copyright 2010 Elsevier Masson SAS.

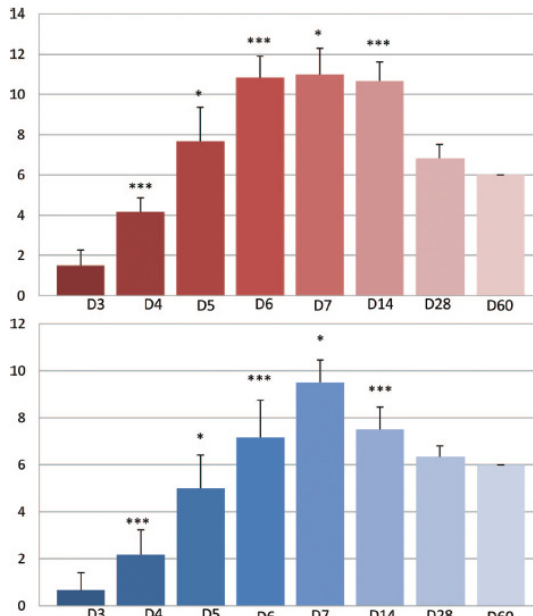
Fig. 4. Macroscopic view of the scar, treated or not treated with RGTA OTR4120 after skin incision. The incision is induced at day 0. RGTA OTR4120 treatment is by topical application (0.1 mg/ml), using a cotton swab, at day 0 before closure by suture and at days 3 and 6. a: untreated skin incision (saline) at day 0; b: untreated skin incision (saline) at day 9; c: RGTA OTR4120 treated skin incision at day 0; d: RGTA OTR4120 treated skin incision at day 9. (Barritault, Garcia-Filipe et al. 2010)

Also severe dermal burns are characterized fibrosis and excessive scarring. On a cellular level aberrant proliferation, inflammation and a changed extracellular matrix architecture are important characteristics for dermal fibrosis. Especially the increased presence of type III collagen is thought to link to the extend of fibrosis (Ulrich, Noah et al. 2002). Ulrich et al. (2003) demonstrated a long term increased type III collagen in fibrous tissue (Ulrich, Noah et al. 2003). In this view, treatments that normalize type III collagen expression without compromising wound healing are of utmost importance. Garcia-Filipe et al. (2007) determined the effects of RGTA OTR4120 administration to a second degree experimental burn on the skin of a hairless rat (Garcia-Filipe, Barbier-Chassefiere et al. 2007). They observed a profoundly improved fibrotic index: this is the ratio of type III collagen over type I collagen. Normalization of the type III collagen / type I collagen ratio also lasted at their final experimental endpoint at 10 months and was caused by a decreased type III collagen production and created a collagen balance that resembled normal skin (Figure 5).



Copyright 2006 Wiley Periodicals, Inc.

Fig. 5. Effect of OTR4120 on the relative proportions of collagen I and collagen III in control skin and burn sites. Three experimental groups were studied: control (healthy skin from untreated rats), burn sites from untreated rats, and burn sites from rats treated with OTR4120. Figure shows the ratio of collagen III over collagen I (fibrotic index) computed using the data in Figures 1 (A,B). Differences compared with control were evaluated using Student’s paired t test; \*p values < 0.05 were considered significant (Garcia-Filipe, Barbier-Chassefiere et al. 2007).



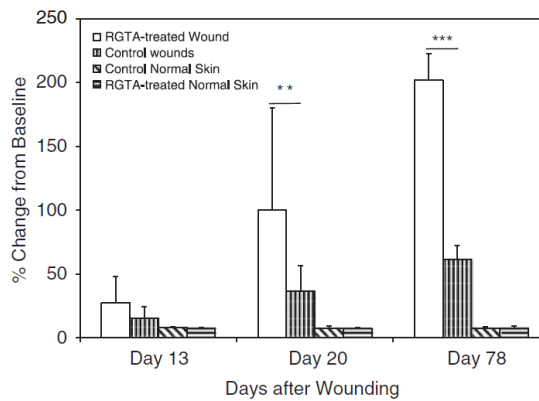
Copyright 2011 by the American Society of Plastic Surgeons.

Fig. 6. Evolution of the mean number of keratinocyte layers. RGTA administration increases the mean number of keratinocyte layers between day 3 and day 7 (above) in comparison with the control group (below). At day 1 and day 2, this number was 0; on and after day 60, this number was 6. (Zakine, Barbier et al. 2011)

A study by Zakine et al. (2011), using this same model, revealed an increased reepithelialisation together with an increased number of keratinocyte layers and blood vessels in the RGTA OTR4120 administered group at the early stages of tissue regeneration that returned to control levels after 1 month post wounding (Figure 6) (Zakine, Barbier et al. 2011).

#### 6.4.3 Full-thickness excisional wounds

Tong et al. studied the effects of RGTA OTR4120 administration to rat full-thickness excisional wounds (Tong, Zbinden et al. 2008; Tong, Tuk et al. 2009). RGTA OTR4120 administration to surgical wounds in rapid healing normal rats significantly improved wound regeneration. RGTA OTR4120 administration promotes epidermal proliferation, increased neodermal granulation tissue deposition, inflammation resolution, improved the vascular response to local heating (Figure 7a), improved collagen maturation and improved the wound breaking strength at all measurement times up to 3 months post wounding (Figure 7b) (Tong, Zbinden et al. 2008; Tong, Tuk et al. 2009).



Copyright 2008 by the Wound Healing Society

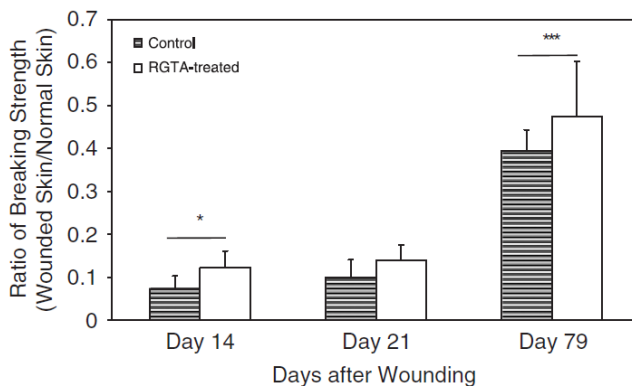
Fig. 7a. The wounded skin and normal skin vascular responses to local heating (44°C for 10 minutes), expressed as the percentages of the increase blood flow over baseline flow, measured by laser Doppler flow with local heat provocation on days 13, 20, and 78 after wounding. Error bars represent the standard deviation. \*\* $p < 0.01$  and \*\*\* $p < 0.001$  indicate the significant differences between treated groups and control groups. (Tong, Zbinden et al. 2008)

#### 6.4.4 Ischemia-reperfusion wounds

Tong et al. (2011) also studied the effects of RGTA OTR4120 administration to ischemia-reperfusion wounds (Tong, Tuk et al. 2011). Similar findings as for the excisional wounds were observed in a cutaneous ischemia-reperfusion model obtained by magnet clamping of a skin fold in the neck area of the animal although with a delayed timing due to the clearance of the necrotic tissue (Tong, Tuk et al. 2011). In addition, monocyte/macrophage staining and CD68 detection on Western blots revealed that RGTA OTR4120 administration facilitated an



inflammation controlled environment that progressed to the normal stages of wound healing.



Copyright 2008 by the Wound Healing Society

Fig. 7b. Wound strength measured as the ratio of the breaking strength of the wounded skin versus that of normal skin on days 14, 21, and 79 after wounding. Error bars represent the standard deviation. \* $p < 0.05$  and \*\*\* $p < 0.001$  indicate the significant differences between treated groups and control groups (Tong, Zbinden et al. 2008; Tong, Tuk et al. 2009).

In summary: the ability of RGTA OTR4120 administration to reduce inflammation; increase angiogenesis; improved healing quality, amongst others reflected by the recurrence of normal dermal collagen balance and an increased tissue breaking strength have now been demonstrated in multiple models (Alexakis, Guettoufi et al. 2001; Alexakis, Caruelle et al. 2004; Alexakis, Mestries et al. 2004; Barbier-Chassefiere, Garcia-Filipe et al. 2009; Tong, Tuk et al. 2011). All are signs of matrix reconstruction to a formulation that more closely resembles normal matrix. Specifically, RGTA OTR4120 decreasing collagen III accumulation, will dramatically reduce the fibrosis that frequently accompanies wound healing. These promising preclinical findings warrant studies on human subjects.

## 6.5 Clinical evidence

The first scientific report on the clinical use of RGTA OTR4120 was a study by Chebbi et al. (2008) who described the effects of local RGTA OTR4120 administration for one month to patients with treatment-resistant corneal-ulcers and to patients with treatment-resistant corneal dystrophy (Chebbi, Kichenin et al. 2008). RGTA OTR4120 administration resulted in the majority of cases in the complete healing of the ulcer. The effect on the keratitis was moderate, however, a significant pain reduction was observed that highly improved the patient's quality of life (Chebbi, Kichenin et al. 2008).

In a within-subject study, Groah et al. (2011) demonstrated the effect of RGTA OTR4120 administration in a patient population of largely persistent pressure ulcers and vascular/venous ulcers (Groah, Libin et al. 2011). The mean duration of the ulcers was 2.5

years. RGTA OTR4120 was administered on the debrided wound, twice weekly for 5 minutes each time. After 4 weeks both a significant reduction in the wound size as well as in the pain perception was found (Groah, Libin et al. 2011).

Van Neck et al. (2011) described the complete healing following of recurrent scalp ulcers RGTA OTR4120 administration (Van Neck, Zuidema et al. 2011).

RGTA OTR4120 also was administered to a 60-year old male patient with a complex medical history. He suffered from obesity (BMI 35), developed type II diabetic over a decade ago and was on insulin treatment. Furthermore, he was known with alcohol and nicotine abuse, heart failure, pacemaker, cardiac and vascular disease and kidney and liver failure. In 1992 and 2002 he has had several toe amputations on both his feet likely caused by his poor cardiac and vascular condition. The patient had developed the diabetic pressure ulcer under investigation on the palmar side of his right foot over 8 months ago. So far, he had been unsuccessfully treated with a wide variety of wound dressings (foams, alginate, hydro colloids, silver dressings, foils, impregnated gauzes and collagen) all applied up to three times weekly if needed. At the start of the OTR4120 treatment the wound measured 2.5 cm<sup>2</sup> (Figure 8A). The wound displayed an almost immediate response to OTR4120 treatment

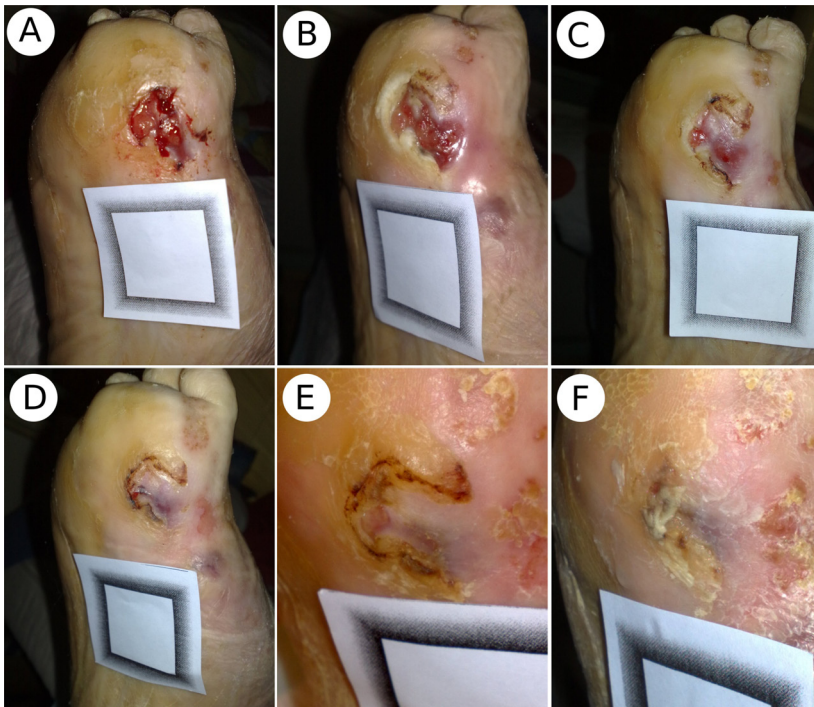


Fig. 8. Diabetic foot of a 60 year old male patient in a state of non-healing for over 8 months. A) day 0, the start of the twice weekly RGTA OTR4120 topical application. At this stage the wound measured 2.5 cm<sup>2</sup>; B) day 7, healthy granulation tissue immediately formed following RGTA OTR4120 treatment; C) day 16; D) day 31, near to complete wound closure; E) day 46; F) day 56, long term closure control. The inner dimensions of the grey shaded square are 30x30mm.

(Figure 8B). Healthy granulation tissue formed and the wound closed in the 5th week of treatment (Figure 8C-E). Further documentation of the wound area proved it remained completely healed (Figure 8F).

## 6.6 Future perspectives

The findings presented support the use of RGTA OTR4120 (CACIPLIQ20®) in treating (chronic) wounds by means of restoring the damaged extracellular matrix.

Research to reduce the complexity of the molecule, to facilitate its synthesis and to increase its effectiveness, is ongoing (Ikeda, Charef et al. 2011). Also oral administration, as a patient friendly means of administration with a RGTA OTR4120 delivery to the side of injury via (micro)circulation, are tested (Charef, Papy-Garcia et al. 2010)

## 7. Concluding remarks

Matrix therapy restores the natural extracellular microenvironment which allows the local cascade of signals to resume in the proper time and order to trigger tissue regeneration. (Barbier-Chassefiere, Garcia-Filipe et al. 2009). Therefore, matrix therapy with engineered biopolymers such as RGTA OTR4120 is simpler and easier to use than cell or gene therapy and is a new alternative in regenerative medicine.

## 8. Acknowledgement

Mr Ronald Lau, Amersfoort, the Netherlands, is thanked for his dedication while applying CACIPLIQ20® to a diabetic foot patient.

The majority of the results presented here were published.

## 9. References

- Agren, M. S. and M. Werthen (2007). "The extracellular matrix in wound healing: a closer look at therapeutics for chronic wounds." *Int J Low Extrem Wounds* 6(2): 82-97.
- Alexakis, C., J. P. Caruelle, et al. (2004). "Reversal of abnormal collagen production in Crohn's disease intestinal biopsies treated with regenerating agents." *Gut* 53(1): 85-90.
- Alexakis, C., A. Guettoufi, et al. (2001). "Heparan mimetic regulates collagen expression and TGF-beta1 distribution in gamma-irradiated human intestinal smooth muscle cells." *FASEB J* 15(9): 1546-1554.
- Alexakis, C., P. Mestries, et al. (2004). "Structurally different RGTAs modulate collagen-type expression by cultured aortic smooth muscle cells via different pathways involving fibroblast growth factor-2 or transforming growth factor-beta1." *FASEB J* 18(10): 1147-1149.
- Attinger, C. E. and E. J. Bulan (2001). "Debridement. The key initial first step in wound healing." *Foot Ankle Clin* 6(4): 627-660.

- Barbier-Chassefiere, V., S. Garcia-Filipe, et al. (2009). "Matrix therapy in regenerative medicine, a new approach to chronic wound healing." *J Biomed Mater Res A* 90(3): 641-647.
- Barrientos, S., O. Stojadinovic, et al. (2008). "Growth factors and cytokines in wound healing." *Wound Repair Regen* 16(5): 585-601.
- Barritault, D., S. Garcia-Filipe, et al. (2010). "[Basement of matrix therapy in regenerative medicine by RGTA((R)): From fundamental to plastic surgery]
- Les bases de la therapie matricielle en medecine regenerative par les RGTA((R)) : du fondamental a la chirurgie plastique." *Ann Chir Plast Esthet* 55(5): 413-420.
- Baum, C. L. and C. J. Arpey (2005). "Normal cutaneous wound healing: clinical correlation with cellular and molecular events." *Dermatol Surg* 31(6): 674-686; discussion 686.
- Branski, L. K., C. T. Pereira, et al. (2007). "Gene therapy in wound healing: present status and future directions." *Gene Ther* 14(1): 1-10.
- Broughton, G., 2nd, J. E. Janis, et al. (2006). "The basic science of wound healing." *Plast Reconstr Surg* 117(7 Suppl): 12S-34S.
- Bullen, E. C., M. T. Longaker, et al. (1995). "Tissue inhibitor of metalloproteinases-1 is decreased and activated gelatinases are increased in chronic wounds." *J Invest Dermatol* 104(2): 236-240.
- Charef, S., D. Papy-Garcia, et al. (2010). "Absorption and tissue distribution of a novel carboxymethyl dextran after oral administration." *Biomed Pharmacother* 64(9): 627-632.
- Charef, S., M. Tulliez, et al. (2010). "Toxicological evaluation of RGTA OTR4120, a heparan sulfate mimetic." *Food Chem Toxicol* 48(7): 1965-1968.
- Chebbi, C. K., K. Kichenin, et al. (2008). "[Pilot study of a new matrix therapy agent (RGTA OTR4120) in treatment-resistant corneal ulcers and corneal dystrophy]
- Etude pilote d'un nouvel agent de therapie matricielle (RGTA OTR4120) dans les ulcères de cornee et les dystrophies corneennes rebelles." *J Fr Ophthalmol* 31(5): 465-471.
- Clark, R. A., J. M. Lanigan, et al. (1982). "Fibronectin and fibrin provide a provisional matrix for epidermal cell migration during wound reepithelialization." *J Invest Dermatol* 79(5): 264-269.
- Colombier, M. L., J. Lafont, et al. (1999). "A single low dose of RGTA, a new healing agent, hastens wound maturation and enhances bone deposition in rat craniotomy defects." *Cells Tissues Organs* 164(3): 131-140.
- Cook, H., K. J. Davies, et al. (2000). "Defective extracellular matrix reorganization by chronic wound fibroblasts is associated with alterations in TIMP-1, TIMP-2, and MMP-2 activity." *J Invest Dermatol* 115(2): 225-233.
- Crovetti, G., G. Martinelli, et al. (2004). "Platelet gel for healing cutaneous chronic wounds." *Transfus Apher Sci* 30(2): 145-151.
- Dash, N. R., S. N. Dash, et al. (2009). "Targeting nonhealing ulcers of lower extremity in human through autologous bone marrow-derived mesenchymal stem cells." *Rejuvenation Res* 12(5): 359-366.
- Diegelmann, R. F. (2003). "Excessive neutrophils characterize chronic pressure ulcers." *Wound Repair Regen* 11(6): 490-495.

- Diegelmann, R. F. and M. C. Evans (2004). "Wound healing: an overview of acute, fibrotic and delayed healing." *Front Biosci* 9: 283-289.
- Dreyfuss, J. L., C. V. Regatieri, et al. (2009). "Heparan sulfate proteoglycans: structure, protein interactions and cell signaling." *An Acad Bras Cienc* 81(3): 409-429.
- Eaglstein, W. H. and V. Falanga (1997). "Chronic wounds." *Surg Clin North Am* 77(3): 689-700.
- Eming, S. A., T. Krieg, et al. (2007). "Gene therapy and wound healing." *Clin Dermatol* 25(1): 79-92.
- Fan, K., J. Tang, et al. (2011). "State of the art in topical wound-healing products." *Plast Reconstr Surg* 127 Suppl 1: 44S-59S.
- Fung, H. B., J. Y. Chang, et al. (2003). "A practical guide to the treatment of complicated skin and soft tissue infections." *Drugs* 63(14): 1459-1480.
- Gandhi, N. S. and R. L. Mancera (2010). "Heparin/heparan sulphate-based drugs." *Drug Discov Today* 15(23-24): 1058-1069.
- Garcia-Filipe, S., V. Barbier-Chassefiere, et al. (2007). "RGTA OTR4120, a heparan sulfate mimetic, is a possible long-term active agent to heal burned skin." *J Biomed Mater Res A* 80(1): 75-84.
- Goldman, R. (2004). "Growth factors and chronic wound healing: past, present, and future." *Adv Skin Wound Care* 17(1): 24-35.
- Groah, S. L., A. Libin, et al. (2011). "Regenerating matrix-based therapy for chronic wound healing: a prospective within-subject pilot study." *Int Wound J* 8(1): 85-95.
- Grotendorst, G. R., Y. Soma, et al. (1989). "EGF and TGF-alpha are potent chemoattractants for endothelial cells and EGF-like peptides are present at sites of tissue regeneration." *J Cell Physiol* 139(3): 617-623.
- Guo, S. and L. A. Dipietro (2010). "Factors affecting wound healing." *J Dent Res* 89(3): 219-229.
- Gurtner, G. C., S. Werner, et al. (2008). "Wound repair and regeneration." *Nature* 453(7193): 314-321.
- Henry, G. and W. L. Garner (2003). "Inflammatory mediators in wound healing." *Surg Clin North Am* 83(3): 483-507.
- Hess, C. T. and R. S. Kirsner (2003). "Orchestrating wound healing: assessing and preparing the wound bed." *Adv Skin Wound Care* 16(5): 246-257; quiz 258-249.
- Hodde, J. P. and C. E. Johnson (2007). "Extracellular matrix as a strategy for treating chronic wounds." *Am J Clin Dermatol* 8(2): 61-66.
- Hubner, G., M. Brauchle, et al. (1996). "Differential regulation of pro-inflammatory cytokines during wound healing in normal and glucocorticoid-treated mice." *Cytokine* 8(7): 548-556.
- Ikeda, Y., S. Charef, et al. (2011). "Synthesis and biological activities of a library of glycosaminoglycans mimetic oligosaccharides." *Biomaterials* 32(3): 769-776.
- Kazakos, K., D. N. Lyras, et al. (2009). "The use of autologous PRP gel as an aid in the management of acute trauma wounds." *Injury* 40(8): 801-805.
- Korting, H. C., C. Schollmann, et al. (2011). "Management of minor acute cutaneous wounds: importance of wound healing in a moist environment." *J Eur Acad Dermatol Venereol* 25(2): 130-137.

- Krishnamoorthy, L., H. L. Morris, et al. (2001). "Specific growth factors and the healing of chronic wounds." *J Wound Care* 10(5): 173-178.
- Lallam-Laroye, C., Q. Escartin, et al. (2006). "Periodontitis destructions are restored by synthetic glycosaminoglycan mimetic." *J Biomed Mater Res A* 79(3): 675-683.
- Lawrence, W. T. and R. F. Diegelmann (1994). "Growth factors in wound healing." *Clin Dermatol* 12(1): 157-169.
- Lazarus, G. S., D. M. Cooper, et al. (1994). "Definitions and guidelines for assessment of wounds and evaluation of healing." *Wound Repair Regen* 2(3): 165-170.
- Lobmann, R., A. Ambrosch, et al. (2002). "Expression of matrix-metalloproteinases and their inhibitors in the wounds of diabetic and non-diabetic patients." *Diabetologia* 45(7): 1011-1016.
- Madden, J. W. and E. E. Peacock, Jr. (1968). "Studies on the biology of collagen during wound healing. I. Rate of collagen synthesis and deposition in cutaneous wounds of the rat." *Surgery* 64(1): 288-294.
- Madlener, M., W. C. Parks, et al. (1998). "Matrix metalloproteinases (MMPs) and their physiological inhibitors (TIMPs) are differentially expressed during excisional skin wound repair." *Exp Cell Res* 242(1): 201-210.
- Martin, P. (1997). "Wound healing--aiming for perfect skin regeneration." *Science* 276(5309): 75-81.
- McGrath, J.A. and Eady, R.A. (1997). "Heparan sulphate proteoglycan and wound healing in skin." *J Pathol* 183(3):251-252.
- Menke, N. B., K. R. Ward, et al. (2007). "Impaired wound healing." *Clin Dermatol* 25(1): 19-25.
- Nathan, C. (2002). "Points of control in inflammation." *Nature* 420(6917): 846-852.
- Nwomeh, B. C., H. X. Liang, et al. (1998). "Dynamics of the matrix metalloproteinases MMP-1 and MMP-8 in acute open human dermal wounds." *Wound Repair Regen* 6(2): 127-134.
- Nwomeh, B. C., H. X. Liang, et al. (1999). "MMP-8 is the predominant collagenase in healing wounds and nonhealing ulcers." *J Surg Res* 81(2): 189-195.
- Okan, D., K. Woo, et al. (2007). "The role of moisture balance in wound healing." *Adv Skin Wound Care* 20(1): 39-53; quiz 53-35.
- Paladini, R. D., K. Takahashi, et al. (1996). "Onset of re-epithelialization after skin injury correlates with a reorganization of keratin filaments in wound edge keratinocytes: defining a potential role for keratin 16." *J Cell Biol* 132(3): 381-397.
- Ramasastry, S. S. (2005). "Acute wounds." *Clin Plast Surg* 32(2): 195-208.
- Rizzi, S. C., Z. Upton, et al. (2010). "Recent advances in dermal wound healing: biomedical device approaches." *Expert Rev Med Devices* 7(1): 143-154.
- Robson, M. C., D. L. Steed, et al. (2001). "Wound healing: biologic features and approaches to maximize healing trajectories." *Curr Probl Surg* 38(2): 72-140.
- Schade, V. L. and T. S. Roukis (2008). "Use of platelet-rich plasma with split-thickness skin grafts in the high-risk patient." *Foot Ankle Spec* 1(3): 155-159.
- Schultz, G. S. and A. Wsocki (2009). "Interactions between extracellular matrix and growth factors in wound healing." *Wound Repair Regen* 17(2): 153-162.
- Sellheyer, K. and D. Krahl (2010). "Skin mesenchymal stem cells: prospects for clinical dermatology." *J Am Acad Dermatol* 63(5): 859-865.

- Servold, S. A. (1991). "Growth factor impact on wound healing." *Clin Podiatr Med Surg* 8(4): 937-953.
- Singer, A. J. and R. A. Clark (1999). "Cutaneous wound healing." *N Engl J Med* 341(10): 738-746.
- Smola, H., G. Thiekotter, et al. (1993). "Mutual induction of growth factor gene expression by epidermal-dermal cell interaction." *J Cell Biol* 122(2): 417-429.
- Steed, D. L., J. B. Goslen, et al. (1992). "Randomized prospective double-blind trial in healing chronic diabetic foot ulcers. CT-102 activated platelet supernatant, topical versus placebo." *Diabetes Care* 15(11): 1598-1604.
- Tong, M., B. Tuk, et al. (2011). "Heparan sulfate glycosaminoglycan mimetic improves pressure ulcer healing in a rat model of cutaneous ischemia-reperfusion injury." *Wound Repair Regen* 19(4):505-514.
- Tong, M., B. Tuk, et al. (2009). "Stimulated neovascularization, inflammation resolution and collagen maturation in healing rat cutaneous wounds by a heparan sulfate glycosaminoglycan mimetic, OTR4120." *Wound Repair Regen* 17(6): 840-852.
- Tong, M., M. M. Zbinden, et al. (2008). "RGTA OTR 4120, a heparan sulfate proteoglycan mimetic, increases wound breaking strength and vasodilatory capability in healing rat full-thickness excisional wounds." *Wound Repair Regen* 16(2): 294-299.
- Tumova, S., A. Woods, et al. (2000). "Heparan sulfate proteoglycans on the cell surface: versatile coordinators of cellular functions." *Int J Biochem Cell Biol* 32(3): 269-288.
- Ulrich, D., E. M. Noah, et al. (2002). "Serum concentration of amino-terminal propeptide of type III procollagen (PIIINP) as a prognostic marker for skin fibrosis after scar correction in burned patients." *Burns* 28(8): 766-771.
- Ulrich, D., E. M. Noah, et al. (2003). "TIMP-1, MMP-2, MMP-9, and PIIINP as serum markers for skin fibrosis in patients following severe burn trauma." *Plast Reconstr Surg* 111(4): 1423-1431.
- Van Neck, J. W., Y. S. Zuidema, et al. (2011). "Unexpected healing of radiation-induced scalp lesions with OTR4120, a heparan sulfate mimetic." *Eur J Dermatol* 21(3): 451-452.
- Velnar, T., T. Bailey, et al. (2009). "The wound healing process: an overview of the cellular and molecular mechanisms." *J Int Med Res* 37(5): 1528-1542.
- Vowden, K. and P. Vowden (2003). "Understanding exudate management and the role of exudate in the healing process." *Br J Community Nurs* 8(11 Suppl): 4-13.
- Walter, D. H., H. Krankenberg, et al. (2011). "Intraarterial administration of bone marrow mononuclear cells in patients with critical limb ischemia: a randomized-start, placebo-controlled pilot trial (PROVASA)." *Circ Cardiovasc Interv* 4(1): 26-37.
- Watt, F. M. and H. Fujiwara (2011). "Cell-extracellular matrix interactions in normal and diseased skin." *Cold Spring Harb Perspect Biol* 3(4).
- Wenk, J., A. Foitzik, et al. (2001). "Selective pick-up of increased iron by deferoxamine-coupled cellulose abrogates the iron-driven induction of matrix-degrading metalloproteinase 1 and lipid peroxidation in human dermal fibroblasts in vitro: a new dressing concept." *J Invest Dermatol* 116(6): 833-839.
- Witte, M. B. and A. Barbul (1997). "General principles of wound healing." *Surg Clin North Am* 77(3): 509-528.

- Wu, Y., R. C. Zhao, et al. (2010). "Concise review: bone marrow-derived stem/progenitor cells in cutaneous repair and regeneration." *Stem Cells* 28(5): 905-915.
- Xia, Y. P., Y. Zhao, et al. (1999). "Effects of keratinocyte growth factor-2 (KGF-2) on wound healing in an ischaemia-impaired rabbit ear model and on scar formation." *J Pathol* 188(4): 431-438.
- Yager, D. R., L. Y. Zhang, et al. (1996). "Wound fluids from human pressure ulcers contain elevated matrix metalloproteinase levels and activity compared to surgical wound fluids." *J Invest Dermatol* 107(5): 743-748.
- Zakine, G., V. Barbier, et al. (2011). "Matrix therapy with RGTA OTR4120 improves healing time and quality in hairless rats with deep second-degree burns." *Plast Reconstr Surg* 127(2): 541-550.